



Post-acute sequelae of SARS-CoV-2 Delta variant infection: A report of three cases in a single family

Chitra Jeyaraj Pandian¹, Jeyaraman Jeyakanthan^{2*} & Rajendran SM^{3*}

¹Department of Biotechnology, Dr. Umayal Ramanathan College for Women
Karaikudi- 630 001, Tamil Nadu, India

²Structural Biology and Biocomputing Lab, Department of Bioinformatics, Alagappa University
Karaikudi- 630 004, Tamil Nadu, India

³CSIR-Central Electrochemical Research Institute, Karaikudi-630 003, Tamil Nadu, India

Received 16 July 2022; revised 27 July 2022

Coronavirus disease 2019 (COVID-19) is caused by Severe Acute Respiratory Syndrome Coronavirus 2 (SARS-CoV-2) that has resulted in global pandemic and crisis in health care system. Several studies have focused only on hospitalized patients with 30 to 90 days after one cycle of illness but post-acute sequelae of COVID-19 existing even after a year remains unclear. Moreover, long-term sequelae in outpatients have not been documented and henceforth myriad clinical sequelae in long haulers continue to evolve. In this study, we report three cases represents a single family presenting several post-acute sequelae one after the other extending beyond one year of recovery. To our knowledge such a case series has not been reported in earlier studies. Herein, we present the sequelae in various organs namely neuropsychiatric (tinnitus, anxiety, depression, insomnia, and posttraumatic stress disorder, cognitive decline), cardiovascular (tachycardia, bradycardia), gastrointestinal (appendicitis) and Dermatologic (erythematous rash and acne) besides ophthalmic manifestations (*conjunctivitis and dry eyes*) in Long-COVID-19 and recommend management strategies.

Keywords: Antiviral Steroid therapy, Appendicitis, Case reports, COVID-19 survivors, Psychopathology, Tinnitus

SARS-CoV-2 has been spreading around the world since December, 2019 with high mortality rate or acute infection and World Health Organization (WHO) declared COVID-19 a pandemic. The delta (B.1.617.2) variant of SARS-CoV-2 was first identified India (Maharashtra) during late 2020 that outcompeted pre-existing lineages namely Kappa (B.1.617.1) and alpha (B.1.1.7)¹. Experimental studies have reported six-fold and eight-fold less sensitive nature of B.1.617.2 to neutralizing antibodies of *convalescent serum* and vaccine-elicited antibodies, respectively, compared to wild-type Wuhan-1 SARS-CoV-2². Moreover, B.1.617.2 showed lower neutralizing antibody titres in ChAdOx1 vaccines than BNT162b2 vaccines [3]. B.1.617.2 also had higher replication efficiency in airway epithelium or organoid with B.1.617.2 spike predominantly existing in cleaved state that further enhanced syncytium formation subsequently displaying lower sensitivity to neutralizing antibody³. The potential dominance of

B.1.617.2 over other lineages could be due to increased spike mediated entry and high replication in B.1.617.2³. Also the mixed lineage circulation during Mid-2021 in India have reduced the efficacy of ChAdOx1 vaccine. This immune evasive B.1.617.2 caused tremendous burden to health care systems in India between April and June, 2021 with more than 200 million cases and high mortality rate. Though most of the patients recovered from acute infection of B.1.617.2, a subset of them sustain persistent symptoms that do not resolve even over a year. Post-acute sequelae of COVID-19 is diagnosed both in patients with severe and mild or asymptomatic infections⁴. Therefore, long-term follow-up investigations to evaluate the post-infectious sequelae in COVID-19 survivors are vital to enhance their diagnosis and survival. Earlier studies have reported that the COVID-19 patients discharged from hospital showed several health issues and persistent symptoms including impaired organ function, depression, detectable abnormalities in imaging techniques, anxiety and declined quality of life⁵⁻⁸. Most of the previous reports⁵⁻⁸ have focused only on early follow-up (after 2-6 months of recovery) while later follow-up

*Correspondence:

E-mail: jkkanthan@gmail.com (JJ)

rajendran_sm@rediffmail.com (RSM)

studies to assess post-acute sequelae in long-COVID-19 (after a year of recovery) and its multi-organ effects are very limited. In the present study, we describe the later follow-up studies, health status and drug tolerance in three cases of a single family with non-severe COVID-19.

Case presentations

Case 1

A 42-year-old female of South Indian origin presented with fever and throat pain on May 11, 2021. She had a past medical history of right ear tinnitus with mild to moderate sensory neural hearing loss (45 dBHz) since 2008 (Fig. 1A) during her last trimester of second baby and normal hearing sensitivity (16.6 dBHz) in the left ear. Brain Magnetic Resonance Imaging (MRI) was normal with bilateral

cerebello-pontine angle cisterns and internal auditory canals without focal lesions or widening of Bilateral (7th – 8th) nerve complexes. Due to delta variant pandemic in India during month of May, 2021, suspecting COVID-19 like symptoms (fever and throat pain), she was treated with azithromycin (500 mg), acetaminophen, levosalbutamol and pan D (combination of pantoprazole- 40 mg and domperidone- 30 mg) along with dexamethasone (4 mg) for 3 days duration. Moreover, she developed high fever of 103°C and fatigue on day 7 of illness and was diagnosed positive for 2019-nCoV in nasopharyngeal swab analysis using Real Time PCR (TaqMan Probe). She was then treated with oral administration of oseltamivir phosphate (75 mg), levosalbutamol, pan D, prednisone (16 mg) and dexamethasone (10 mg) for next 3 days followed

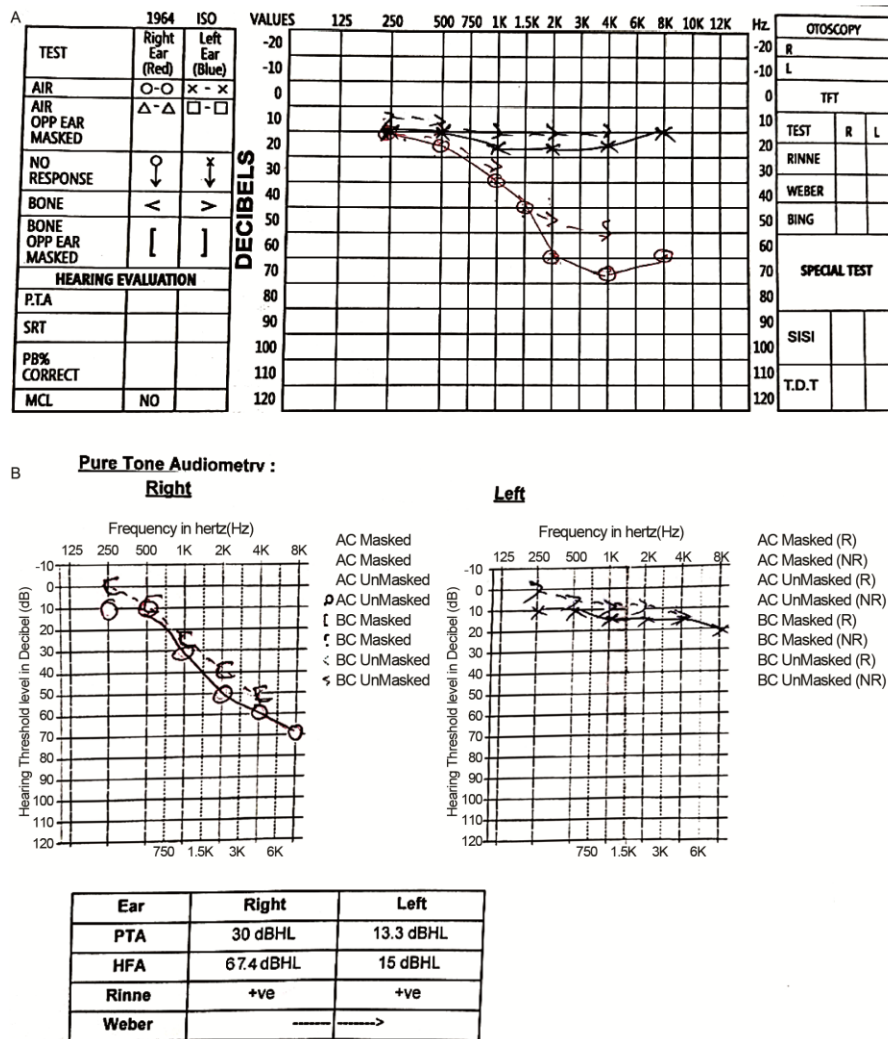


Fig. 1 — (A) Audiogram of Case 1 before SARS-CoV-2 infection with mild sensory hearing loss in right ear; & (B) Audiogram of Case 1 after COVID infection and tinnitus with moderate-severe sensory hearing loss (high frequency hearing loss pattern) in the right ear

by Intravenous (IV) administration of dexamethasone (8 mg shredder), pantoprazole (40 mg shredder) and paracetamol (1000 mg). Next day due to persistent fever, computed tomography (CT) scan with serial thin axial section of chest was done without IV involvement. The audiogram in phase of COVID pneumonia presented worsening of tinnitus (Fig. 1B) with severe sensory neural hearing loss (67.4 dBHz) in right ear. Multifocal patchy ill-defined ground glass densities with peripheral and central distribution was noted in both lung fields evidencing typical COVID-19 pneumonia (Co-RADS 5) with severity score of 5 and 16-18% of lung involvement (Fig. 2A & B).

CRP and D-dimer biomarkers were found to be 37 mg/dL and 390 ng/mL (FEU), respectively. Methylprednisolone (8 mg for 13 days), Favipiravir (200 × 4 mg for 13 days), osteltamir (75 × 2 mg for 3 days) was started on May 18, 2021 along with azithromycin (200 × 2 mg for 14 days), blood thinner clopidogrel (for 35 days), vitamin supplement (Vitamin B complex and C) and pantoprazole- 40 mg (with combination of 20 mg Domperidone for next one month). Seven days after above treatment, the CRP, D-dimer, blood sugar and haemoglobin levels were found to be 82 mg/dL, 420 ng/mL (FEU), 93 mg/dL and 11%, respectively. The chest CT scan report on May 30, 2021 indicated multifocal areas of dense subpleural fibrotic changes in both lung fields evidencing late phase of COVID pneumonia with post-inflammatory sequelae (Fig. 2C).

The patient had developed sudden lactation after treatment from June 9, 2021 onwards and the all the medicines were tapered and withdrawn completely. One week after the withdrawal, the patient developed

severe heart palpitations, fatigue, muscle weakness, joint pains, recurrent headache and vertigo. The patient was then queried for nerve related issues and correlated both clinically and by MRI scan (Fig. 3A-C). No significant abnormality was observed in brain parenchyma and no evidence of acute infarct or hemorrhage or space-occupying lesions (SOL) was identified in brain MRI. Electroencephalogram (EEG) findings were normal and no detectable spike 1 or 2 protein or nucleoproteins or SARS-CoV-2 RNA was found in cerebrospinal fluid analysis performed using RT-PCR.

The The pituitary gland and Pituitary stalk appeared normal measuring 6 mm (CC) × 10 mm (AP) × 10 mm (TR) and prolactin levels was found to be normal (18.86 ng/mL) and therefore interpreted that milk secretion could be due to side effect of Domperidone drug (used in combination with pantoprazole). Serum thyroid profile study of Triiodo thyronine (T3), Serum thyroid profile showed Triiodo thyronine (T3), Thyroxine (T4) and Thyroid stimulation hormones (TSH) was found to be 1.09 ng/mL, 11.24 µg/dL and 2.83 IU/mL, respectively. The patient was also treated for steroid-induced malassezia folliculitis with topical antifungals. Ophthalmic manifestations such as conjunctivitis and dry eyes were also noted in the patient and was treated with lubricants and moxifloxacin eye drops. Table 1 represents the Complete Hemogram Test of the patient with interleukin-6 with less than 2.7 pg/mL. The patient also presented hair loss, joint pain, worsening of premenstrual syndrome and change in menstrual frequency.

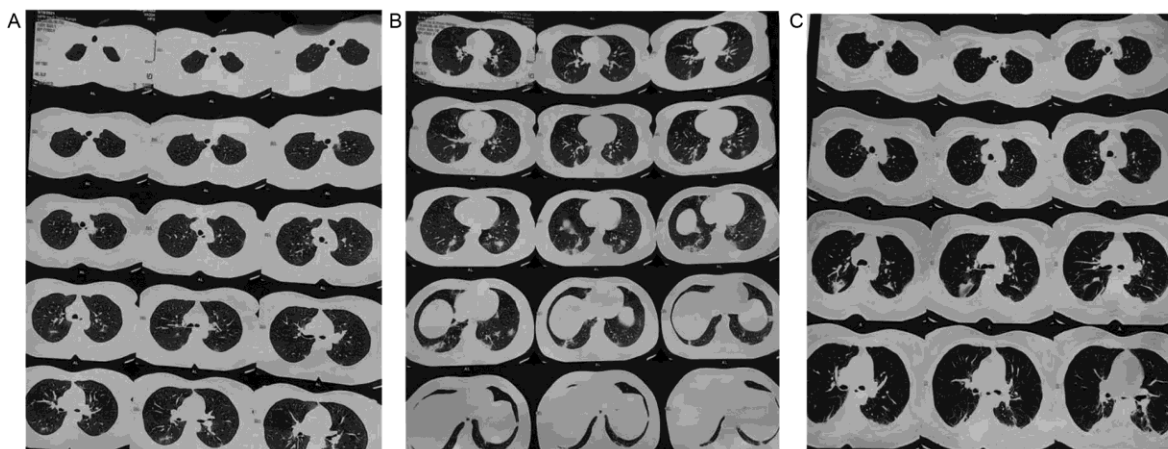


Fig. 2 — (A & B) Serial thin axial section of Chest CT without IV contrast in Case 1 showing multifocal patchy ground glass densities with peripheral and central distribution in both lung fields; and (C) Chest CT of Case 1 indicating multifocal areas of dense subpleural fibrotic changes in both lung fields

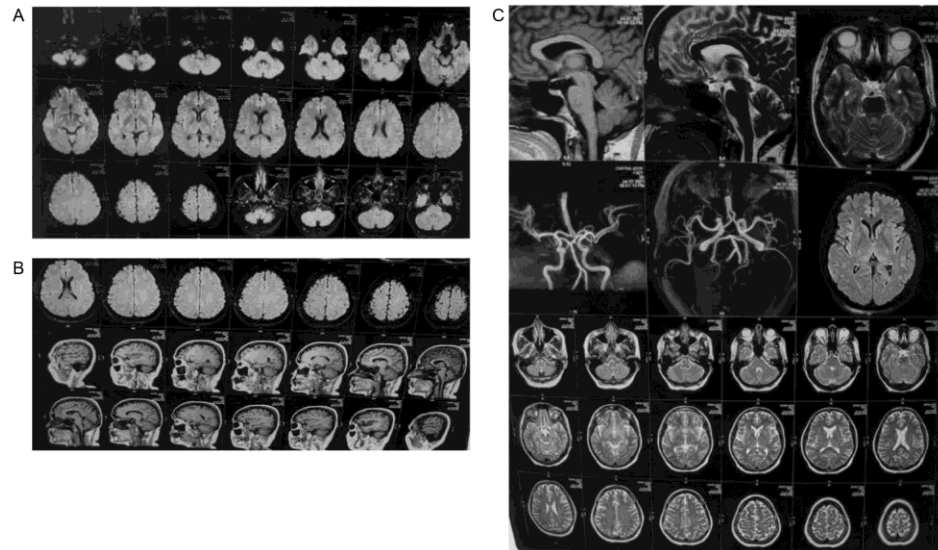


Fig. 3 — Post-Covid-19 Intracranial, Non-contrast MRI of case 1 showing no significant abnormality in brain parenchyma or no evidence of acute infarct/ Hemorrhage/SOL

Table 1 — Complete Hemogram Test of case 1

Test Name	Values	Units	Reference Range
Total Leucocyte Count	5.86	$\times 10^3/\mu\text{L}$	4.0 – 10.0
Neutrophils	62.5	%	40 – 80
Lymphocyte percentage	32.1	%	20 – 40
Monocytes	3.4	%	0 – 10
Eosinophils	1.2	%	0 – 6
Basophils	0.5	%	< 2
Immature Granulocyte percentage (IG%)	0.3	%	0 – 0.4
Neutrophils – Absolute count	3.66	$\times 10^3/\mu\text{L}$	2 – 7
Lymphocytes – Absolute count	1.88	$\times 10^3/\mu\text{L}$	1 – 3
Monocytes – Absolute count	0.2	$\times 10^3/\mu\text{L}$	0.2 – 1.0
Basophils – Absolute count	0.03	$\times 10^3/\mu\text{L}$	0.02 – 0.1
Eosinophils – Absolute count	0.07	$\times 10^3/\mu\text{L}$	0.02 – 0.5
Immature Granulocyte (IG)	0.02	$\times 10^3/\mu\text{L}$	0 – 0.3
Total RBC	4.21	$\times 10^3/\mu\text{L}$	3.9 – 4.8
Nucleated RBC	Nil	$\times 10^3/\mu\text{L}$	<0.01
Nucleated RBC %	Nil	$\times 10^3/\mu\text{L}$	<0.01
Hemoglobin	11.8	g/dL	12 – 15
Hematocrit (PCV)	41	%	36 – 46
Mean corpuscular volume (MCV)	97.4	fL	83 – 101
Mean corpuscular Hemoglobin (MCH)	28	g/dL	27 – 32
Mean corpuscular Hemoglobin concentration (MCHC)	28.8	g/dL	31.5 – 34.5
Red cell distribution width – SD (RDW-SD)	56.2	fL	39 – 46
Red cell distribution width – SD (RDW-CV)	15.8	%	11.6 – 14
Platelet distribution width (PDW)	8.4	fL	9.6 – 15.2
Mean Platelet volume (MPV)	8.2	fL	6.5 – 12
Platelet Count	309	$\times 10^3/\mu\text{L}$	150 – 400
Platelet to large cell ratio (PLCR)	11.3	%	19.7 – 42.4
Plateletcrit (PCT)	0.25	%	0.19 – 0.39

Based on the above diagnostics, the patient was treated with propranolol (40 mg), betahistine (16 mg), cholecalciferol and naproxen from July 22, 2021 onwards. Five days after treatment with propranolol, the patient suffered bradycardia, low blood pressure and persistent headache. The patient was then found to suffer from psychopathological sequelae including insomnia, panic attack, delirium, racing thoughts and anxiety. The patient was then treated with clonazepam, escitalopram, probiotics, multivitamins and minerals for four months from July to October, 2021. After one week of treatment, the patient suffered from ocular complications due to side-effects of aforesaid psychotropic drugs that includes eye flashes, blurred vision, eye floaters and eye pain. However, the patient's retinal imaging was found to be normal.

The patient was recommended to taper and withdrew the psychotic drugs due to adverse side effects. Due to numerous side effects and withdrawal effects of steroids, domperidone and psychotropic medications, herbal drugs were then used for treatment that includes 300 mg of root extract of *Withania somnifera*, 500 mg of leaf extracts of *Centella asiatica* and water decoction of flower of *Convolvulus pluricaulis* (1-2 g) in divided doses every

day for next eight months till June 2022. Deep breathing and guided meditation were also suggested to enhance mental health and recovery from COVID-related anxiety and stress. Case 1 is a typical example of COVID-19 long hauler and both the viral infection and medication side effects have severely affected the quality of life and physical/mental health outcomes of the patient.

Case 2

A 49-year-old male (spouse of case 1) with a past history of hypertension was diagnosed with COVID-19 on May 1. He had laryngitis without fever since April 23 and was treated with azithromycin (500 mg), levocetirizine, montelukast and other nonsteroidal anti-inflammatory drugs from May 1 onwards for 6 days. Due to persistent fever, he was treated with Intravenous administration of Dexamethasone (8 mg shredder), Pantoprazole (40 mg shredder) and paracetamol (1000 mg IV) followed by oral administration of prednisolone (16 mg), oseltamivir (75 mg) along with azithromycin and pan D (combination of pantoprazole- 40 mg and domperidone- 30 mg) for next 6 days.

On day 12 of illness (May 12), he was admitted in hospital due to worsening oxygen saturation ($PO_2 = 85$ mmHg) with D-dimer and CRP of

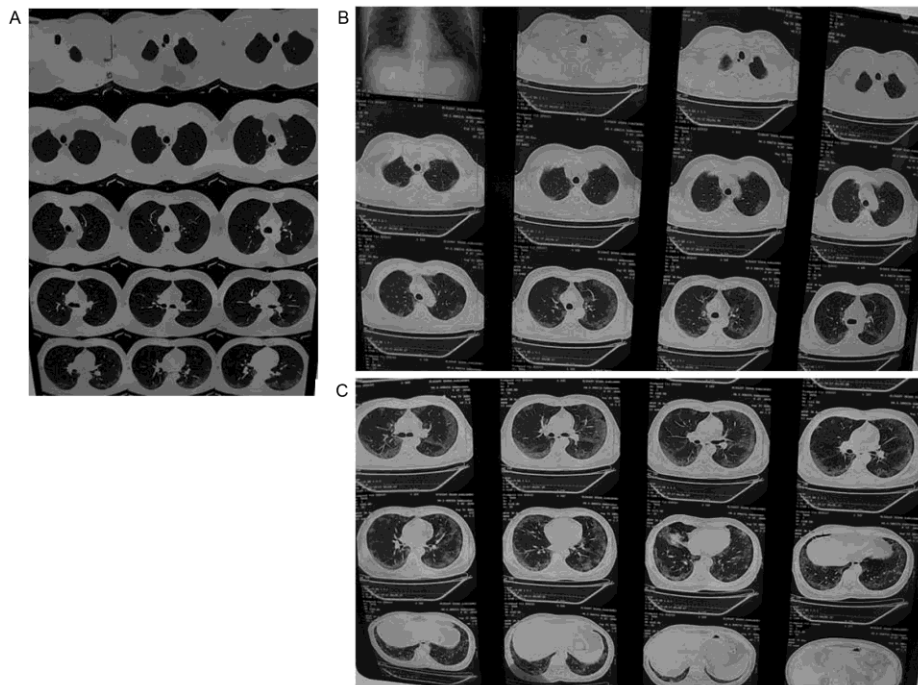


Fig. 4 — (A) Chest CT of Case 2 showing multiple peripheral patchy areas of ground-glass opacities and interlobular septal thickening noted in all lobes of bilateral lung fields; (B and C) Non-contrast Chest CT images of Case 2 showing multiple wedge shaped patchy opacities and ground glass areas noted in both the lungs more in bilateral posterior aspect and lower regions

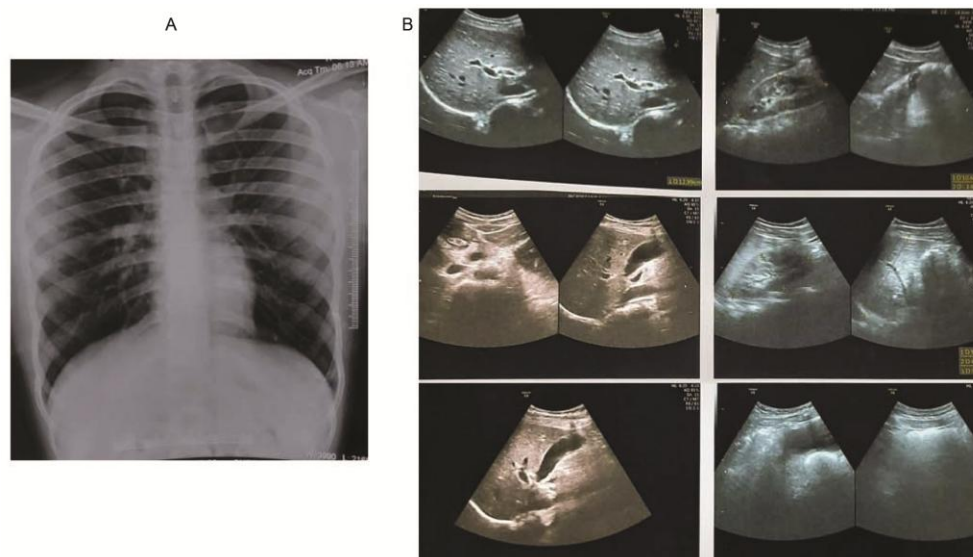


Fig. 5 — (A) Chest X-ray of Case 3 showing mild lung inflammation; & (B) Sonography of Case 3 showing Acute Suppurative appendicitis

840 ng/mL and 80 mg/L after intravenous administration of Betnesol and paracetamol. The chest CT scan (Fig. 4A) of patient showed multiple wedge shaped peripheral patchy opacities and ground glass areas were noted in both the lungs more in bilateral posterior aspect and lower regions (typical of viral pneumonia) with spondylotic changes at spine. The CT severity score was assigned as 17 out of 25 based on the percentage area involved in each of the 5 lobes and the percentage of lung involvement was found to be 55%. Remdesivir was initiated on May 12 and discontinued on May 16. Since the viral load of SARS-CoV-2 was constantly negative, oxygen was weaned off on day 16 of illness and the patient was discharged on May 17. Favipiravir and oseltamivir along with clopidogrel was also continued for next 7 days and then gradually withdrawn. However, the patient presented erythematous rash, tachycardia, hair loss and extreme fatigue. On one week of follow-up, the haematological parameters were normal (including CRP- 5.6 mg/L, D-Dimer-140 ng/mL (FEU), Blood sugar- 109 mg/dL) and the CT scan (Fig. 4B, 4C) showed multiple peripheral patchy areas of ground glass opacities and interlobular septal thickening noted in all lobes of bilateral lung fluids besides bilateral perinephric fat stranding with 45% of lung involvement. Favipiravir and oseltamivir was continued for 7 more days to improve the clinical outcome of the patient. The patient reported conjunctivitis and dry eyes as in Case 1 and was treated with lubricants and antibiotic eye drops.

Case 3

A 16 year old male patient (son of case 1) presented with fever and throat pain on May 10. He was diagnosed for SAR-CoV-2 infection in nasopharyngeal swab analysis and was treated with azithromycin, acetaminophen, levosalbutamol and pantoprazole along with dexamethasone and methylprednisolone (4 mg) for 7 days till May 16. Later on July 17, 2021 the child had severe and persistent stomach pain. The child had no obvious inducement for stomach pain before. His temperature was normal and denied a history of allergies to drug or food.

Due to clear history of SAR-CoV-2 infection, routine examination was done in external hospital that showed 15-20/hpf pus cells and 2-4/hpf epithelial cells in urine besides normal glucose (98 mg/dL), urea (26.4 mg/dL), creatinine (0.7 mg/dL), sodium (137 mEq/L), Potassium (308 mmol/L), chloride (102 mmol/L), bicarbonate (22 mmol/L) besides negative for Hepatitis antigen, non-reactive HCV and for COVID-19 swab antigen. The haematological investigation showed 12.1 g/dL hemoglobin, 8290 cells/cumm total WBC, 64% neutrophil, 29% lymphocyte, no basophil, 5% monocyte, 2% eosinophil, 4.2 ML/10⁹ total RBC count, 35.5% hematocrit, 187000 lakhs/Cumm platelet count, 84.3 MCV, 28.7 MCH, 34.1 MCHC, 18 mm/1 h Erythrocyte sedimentation rate, 6 min 45 sec of clotting time, 16.2 IU/L SGOT, 10 IU/L SGPT, 83.8 total alkaline phosphatase, 1.2 mg/dL total bilirubin,

0.8 mg/dL bilirubin (direct), 0.4 mg/dL bilirubin (indirect), 6.7 g/dL total protein, 3.6 g/dL serum albumin and 3.1 g/dL serum globulin.

Since the child had SARS-CoV-2 infection two months before the onset of abdominal pain, he was admitted in the hospital for further diagnosis. On examination, his vital signs were normal (Pulse rate- 73 beats/min, blood pressure- 120/70 mmHg, Respiratory rate- 18/min, SPO₂- 98% in room air). Since the patients have a history of allergic rhinitis, mild lung inflammation was noted in chest X-ray (Fig. 5A), however the Respiratory B/L NVBS examination was normal. But then abdominal examination of case 3 showed soft and tenderness in right iliac fossa.

The 4D real time volume sonography (Fig. 5B) of the patient showed acute suppurative appendicitis with patchy mucosal disruption with minimal pero appendiceal fluid, mild appendicular mass, endocolitis and reactive hepatitis. Mild antral gastritis and non-obstructive left renal concretion was also noted. High resolution sonography of the bowel showed wall thickening in pylorus of stomach and mural stratification preserved besides mild mucosal irregularity. Moreover Graded compression of Sonography of Right Iliac fossa revealed tubular peristaltic bowel like structure of blind ending of lumen diameter measuring 6.7 mM with thickened and edematus appendicular wall. Patchy mucosal disruption, mild peri appendiceal fat stranding and caking representing mild appendicular mass of 10 × 8.6 × 7.6 mm was noted. Minimal peri appendiceal fluid was noted and appendix appeared fluid filled. Therefore laparoscopic appendectomy was done on July 20, 2021 and was subsequently treated with IV of antibiotics, anti-inflammatory, vitamin supplements and other supportive measures. He was symptomatically better and hence discharged on July 22, 2021.

Discussion

SARS-CoV-2 infection displayed huge effects on mental health both directly and indirectly due to prolonged physiological and psychosocial stress, respectively. In this case series, we report various scenarios that highlight the onset of neuropsychiatric symptoms, hypertension and appendicitis as sequela in SARS-CoV-2 patients that can be either due to direct viral infection of central nervous system (CNS), endothelial dysfunction (resulting in hypertension) and gastrointestinal systems or indirect inflammation

of the organs in setting of infection or steroid toxicity or combination of aforesaid.

The direct injury caused by SARS-CoV-2 infection can be due to wide distribution of host cell angiotensin converting enzyme- 2 (ACE2) receptors in blood brain barrier capillary cells (CNS), intestine, lungs, neurons, glia, kidneys and endothelium. Also, the secondary inflammation of brain, lungs and gastrointestinal systems can also be a plausible etiology for physiological sequela and neuropsychiatric pathogenesis. Moreover, corticosteroids have been proposed as a therapeutic component in SARS-CoV-2 hyper-inflammatory setting. Though, the corticosteroid induced psychosis in COVID-19 survivors can be the result of corticosteroid imbalance or neuronal toxicity induced by glutamate⁹, the neuropsychiatric symptoms have not been well documented in literature and further studies are necessary to define this complex etiology.

In this report, post-COVID infectious state of Case 1 with neuropsychiatric symptoms are broad with i) normal MRI findings, ii) no detectable spike 1 or 2 protein or nucleoproteins in CSF, iii) no detectable SARS-CoV-2 RNA in CSF (RT-PCR) and iv) normal EEG findings that raises suspicion for encephalitis owing to clinical similarities. Sudden onset of neuropsychiatric symptoms in COVID-19 infected patients (as in case 1) also increases the concern for SARS-CoV-2 invasion causing encephalitis as reported in early studies¹⁰. Since the neuropsychiatric pathogenesis in post-COVID patients remains limited, symptomatic management is the suitable strategy. However, antibody (IV) treatment is warranted and clinical improvement can be monitored with pre-or post-COVID therapy with neuro-cognitive analysis and repeated imaging data.

The Case 1 data also evidenced the deleterious effect of SARS-CoV-2 infection in auditory system (tinnitus). Absence of major symptoms in case 1 does not indicate healthy cochlear function. Damage in auditory system or tinnitus in post-COVID condition in case 1 could be typically intracochlear or viral damage to auditory brainstem or organ of Corti or spiral ganglion or stria vascularis as reported in literature¹¹. However, audiological test for Case 1 evidenced a high frequency hearing loss pattern in the right ear that could be induced by SARS-CoV-2 infection. Therefore, besides other clinical examinations, detailed history, audiological diagnostics and close monitoring are mandatory in evaluating COVID patients with tinnitus.

The severity of COVID infection in Case 2 with low oxygen saturation, higher levels of D-dimer/CRP biomarkers and pre-existing hypertension followed by remdesivir treatment could be attributed to arterial/venous thrombosis and inflammation as reported in earlier studies¹². Therefore, Case 2 data indicate that hypertension could be one of the risk factors to increase the severity of SARS-CoV-2 infection and its multidisciplinary management is vital for favourable outcome in hypertensive patient.

COVID-19 infection contributing to pathogenesis of acute appendicitis in Case 3 could be attributed to the binding of SARS-CoV-2 to highly expressed ACE-2 receptor in intestinal lining or prolonged viral shedding in faeces as reported in earlier animal model study^{13,14}. As reported in literature¹⁵ post-acute sequelae in Covid-19 survivors could be mediated by acute injury to one/ multiple organs or certain tissues serving as persistent SARS-CoV-2 reservoirs or immune dysregulation, interactions of SARS-CoV-2 with host microbiome or debilitated brainstem/ vagus nerve signalling or primed immune cells activity or molecular mimicry of SARS-CoV-2 protein with human proteins resulting in autoimmunity

Based on the imaging and clinical data of these case studies, it is clear that recovering from COVID-19 infection is just the beginning of several complicated damaging effects of virus on both body and mind. Considering the alarming effect of SARS-CoV-2 infection, we now suggest careful clinical scrutinization of new onset or exacerbated pathological conditions is essential in COVID-19 survivors, to provide appropriate therapeutic options for reducing the disease burden which is expected to be high in patients with pre-existing neurological or hypertensive or gastrointestinal conditions. Moreover, therapeutic decision-making must be applied based on balancing potential risks and benefits in use of steroids such as methylprednisolone/dexamethasone to hospitalized or non-hospitalized patients in developing immediate or long-term neuropsychiatric complications. The individualized nature of Post-acute sequelae symptoms suggests the urgent need to implement personalized therapy approach to provide best therapeutic care for specific patients and precision treatment for patients with pre-existing conditions to improve the clinical outcomes. Furthermore, both cognitive and physical rehabilitation care is essential for COVID-19 long haulers experiencing debilitating illness.

Conclusion

Several clinical sequelae of SARS-CoV-2 infectious processes were evidenced in aforesaid case series particularly mental health sequelae (anxiety, depression, insomnia, and posttraumatic stress disorder), central nervous system sequelae (cognitive decline), cardiovascular sequelae (tachycardia, bradycardia), gastrointestinal sequelae (appendicitis), cutaneous sequelae (erythematous rash and acne) and constitutional sequelae (fatigue) were observed besides ophthalmic manifestations. The case series also suggests that SARS-CoV-2 infection or corticosteroids therapy or therapeutic options can result in predisposition to neuropsychiatric complications in COVID-19 survivors, necessitating further investigations to elucidate its mechanism on central nervous system effects and to recommend mitigation strategies in early phase of infection. Moreover, further studies are warranted to understand the pharmacologic or viral drivers on gastrointestinal pathogenesis and residual or ongoing symptoms in children and adolescents after SARS-CoV-2 infection. Besides, it is evident that care for COVID-19 patients didn't conclude when infection subsides, and therefore interdisciplinary aid is necessary for comprehensive care of long haulers with persistent symptoms in outpatient setting. Also, it is essential for healthcare systems to establish dedicated COVID-19 clinics with multi-disciplinary specialists to provide integrated care for post-acute sequelae in COVID-19 survivors.

Acknowledgement

JJ gratefully acknowledges the MHRD-RUSA 2.0 [F. 24/51/2014-U, Policy (TNMulti-Gen), Dept. of Edn. Govt. of India] for the infrastructure facilities provided to the Department of Bioinformatics, Alagappa University. JJ thanks DST INDO-TAIWAN (GITA/DST/TWN/P-86/2019 dated: 04/03/2020) for funding. JJ thanks TANSCHER [RGP/201920/ALU/HECP-0049], Indo-Taiwan [GITA/DST/TWIN/P-86/2019] dated: 04/03/2020, DBT(BIC)-No. BT/PR40154/BTIS/137/34/2021, DST-Fund for Improvement of S&T Infrastructure in Universities & Higher Educational Institutions (FIST) (SR/FST/LSI-667/2016) (C), DST Promotion of University Research and Scientific Excellence (PURSE) (No. SR/PURSE Phase 2/38 (G), 2017.

Conflict of interest

All authors declare no conflict of interest.

References

- 1 Chaudhary S, Rai P, Sesham K, Kumar S, Singh P, Chandra TN, Pratima Chaudhuri, Anjan Trikha & Yadav SC, Microscopic imaging of bronchoalveolar fluids of COVID-19 positive intubated patients reveals the different level of SARS-CoV-2 infection on oral squamous epithelial cells. *Indian J Biochem Biophys*, 58 (2021) 196.
- 2 Huang Y, Tan C, Wu J, Chen M, Wang Z, Luo L, Zhou X, Liu X, Huang X, Yuan S, Chen C, Gao F, Huang J, Shan H & Liu J, Impact of coronavirus disease 2019 on pulmonary function in early convalescence phase. *Respir Res*, 21 (2020) 163.
- 3 Shatabdi G, Sanjit D & Sujoy G, Diabetes in the time of COVID-19 pandemic: A knife with two sharp ends. *Indian J Biochem Biophys*, 57 (2020), 512.
- 4 Lerum TV, Aalokken TM, Bronstad E., Aarli B, Ikdahl E, Lund K, Durheim MT, Rodriguez JR, Meltzer C, Tonby K, Stavem K, Skjonsberg OH, Ashraf H, & Einvik G, Dyspnoea, lung function and CT findings 3 months after hospital admission for COVID-19. *Eur Respir J*, 57 (2021) 2003448.
- 5 Huang C, Huang L, Wang Y, Li X, Ren L, Gu L, Kang L, Guo L, Liu M, Zhou X, Luo J, Huang Z, Tu S, Zhao Y, Chen L, Xu D, Li Y, Li C, Peng L, Li Y, Xie W, Cui D, Shang L, Fan G, Xu J, Geng W, Ying W, Jingchuan Z, Chen W, Jianwei W, Dingyu Z & Bin C, 6-month consequences of COVID-19 in patients discharged from hospital: a cohort study. *Lancet*, 397 (2021) 220.
- 6 Van den Borst B, Peters JB, Brink M, Schoon Y, Bleeker-Rovers CP, Schers H, Hieronymus WHV, Hanneke VH, Mark van den B, Hans van der H, Monique HR, Mathias P, Jan V & Michel van den H, Comprehensive health assessment three months after recovery from acute COVID-19. *Clin Infect Dis*, 73 (2021) e1089.
- 7 Bellan M, Soddu D, Balbo PE, Baricich A, Zeppego P, Avanzi GC, Giulia B, Giuseppe B, Marco B, Sofia B, Valeria B, Margherita B, Vincenzo C, Luigi MC, Elisa C, Carlo C, Martina C, Alessandro C, Daria C, Carla DB, Simona De V, Alessandro F, Martina G, Eleonora G, Eleonora G, Carla G, Leonardo G, Chiara G, Eyal H, Amalia J, Marco I, Luca L, Lucia L, Maria M, Paolo M, Erica M, Antonio P, Elena P, Filippo P, Giuseppe P, Alice P, Pierluigi P, Riccardo Q, Cristina R, Pier PS, Camilla V, Erika Z & Mario P, Respiratory and psychophysical sequelae among patients with COVID-19 four months after hospital discharge. *JAMA Netw Open*, 4 (2021) e2036142.
- 8 Zhou F, Tao M, Shang L, Liu Y, Pan G, Jin Y, Wang L, Hu S, Li J, Zhang M, Fu Y & Yang S, Assessment of Sequelae of COVID-19 Nearly 1 Year After Diagnosis. *Front Med*, 8 (2021) 717194.
- 9 David A, Forero P, Matthew MH, Iriana Paola Mozo H, Ivan Bolívar Collado E, Joselyn P, Carlos F, David MF, Andrea LM, Viledy LV, Natasha A, Camejo A, Emilia MS, Lourdes AD, Luis AP, Carlos GM, María EL & Alberto EP, Remitting neuropsychiatric symptoms in COVID-19 patients: Viral cause or drug effect. *J Med Virol*, 94 (2022) 1154.
- 10 Torrico T, Kiong T, Assumpcao C, Aisuenu U, Jaber F, Sabetian K, Molla M, Kuran R & Heidari A, Postinfectious COVID-19 Catatonia: A Report of Two Cases. *Front. Psychiatry*, 12 (2021) 696347.
- 11 Pramod C, Al Hail AN, Nasfaren Z & Deepak SV, COVID-19 and Tinnitus. *Ear Nose Throat J*, 100 (2021) 160S.
- 12 Peng M, He J, Xue Y, Yang X, Liu S & Gong Z, Role of Hypertension on the Severity of COVID-19: A Review. *J Cardiovasc Pharmacol*, 78 (2021) e648.
- 13 Jessica SM, Grant R, Shannon M, Daniel L, Eugene M, Katye H, Melinda P, Linda W & Shirley DB, Acute appendicitis in four children with SARS-CoV-2 infection. *J Pediatr Surg Case Rep*, 64 (2021) 101734.
- 14 Soo-kyung P, Chil-Woo L, Dong-II P, Hee-Yeon W, Hae Suk C, Ho Cheol S, Kwangsung A, Min-Jung K & Eun-Jeong J, Detection of SARS-CoV-2 in Fecal Samples from Patients with Asymptomatic and Mild COVID-19 in Korea. *Clin Gastroenterol Hepatol*, 19 (2021) 1387.
- 15 Proal AD & Van Elzakker MB, Long COVID or Post-Acute Sequelae of COVID-19 (PASC): An Overview of Biological Factors That May Contribute to Persistent Symptoms. *Front Microbiol*, 12 (2021) 698169.