



Hepatoprotective potential of isolated flavonoids from *Trapa natans* L. against the paracetamol induced oxidative stress in rats

Chandana Majee^{1*}, Rupa Mazumde¹ & Alka N Choudhary²

¹Department of Pharmaceutical Chemistry, Noida Institute of Engineering & Technology (Pharmacy Institute),
19 Knowledge Park II, Institutional Area, Greater Noida – 201 306, Uttar Pradesh, India

²Department of Pharmaceutical Chemistry, Shri Guru Ram Rai University, Dehradun, Patel Nagar,
Dehradun - 248 001, Uttarakhand, India

Received 07 October 2021; revised 26 September 2022

Overdose of paracetamol causes liver toxicity, due to oxidative stress by the reactive oxygen species (ROS) that increases the levels of ALT and AST, and reduces the level of the antioxidant enzymes. Flavonoids are a source of natural antioxidants that assist in neutralization of ROS. Several studies have suggested that flavonoids can help protect the liver. The Water Chestnut, *Trapa natans* L. plants have long been used in the traditional system of medicine and possess considerable antioxidant potential. In this study, we tried to isolate flavonoids from *T. natans* L. and evaluate the hepatoprotective potential of the isolated compound. We isolated flavonoids from the extract of the aerial part of plant and characterized by UV, IR, NMR and Mass spectroscopy. The isolated flavonoid was induced orally once a day (30 mg/kg). The test drug (isolated compound) could lower the elevated levels of serum enzymes such as glutamate oxaloacetate transaminase (AST), serum glutamate pyruvate transaminase (ALT), alkaline phosphatase (ALP) and total bilirubin. Silymarin (30 mg/kg) was taken as a standard drug that exhibits significant hepatoprotective activity against the paracetamol induced hepatotoxicity model in Wistar albino rats. The histopathological study of rat liver also strengthens biochemical evaluation analysis. Based on the experimental results, it can be concluded that the isolated flavonoids act as hepatoprotective agents in rats.

Keywords: Antioxidant, Liver toxicity, Reactive oxygen species, Water Chestnut

The liver plays the most important role in digestion and metabolism. In the case of hepatic diseases the hepatic cell, and tissues were affected and the shape of the liver also changed¹. Approximately 20,000 deaths occur every year due to liver disease². Reactive oxygen species (ROS), especially oxygen-free radicals, have been involved in the pathogenesis of a variety of degenerative diseases, including certain hepatopathies, according to numerous investigations. Oxidative stress has a key role in the pathophysiology of paracetamol liver injury³. Paracetamol metabolism, glutathione depletion, and covalent binding of the reactive metabolite N-acetyl-p-benzoquinone imine to cellular proteins are all crucial intracellular processes in cell death^{4,5}.

Herbal medicines get popularity due to less side effects, ease of availability, and low cost. Several traditional antioxidants have been demonstrated *in vitro* and *in vivo* investigations to protect hepatocytes from

lipid peroxidation and inflammation, avoiding the development of hepatic necrosis^{6,7}. *Trapa natans* L., a well known herb in the Indian Ayurveda system of medicine, generally known as Water chestnut and locally, Singhara, belongs to the family Trapaceae. In traditional medicine, it is used to treat ailments of stomach, liver, kidney, spleen, and genitourinary system⁸. It contains high amount of polyphenolic compounds and flavonoids and exhibit significant antioxidant activity and potential to cure hepatic diseases^{9,10}. Therefore, in this investigation, we adopted a paracetamol induced oxidative stress model to examine the hepatoprotective potential of the flavonoids isolated from *T. natans* plant extract.

Materials and Methods

Paracetamol and silymarin were procured from Sigma-Aldrich, USA. The analytical kit for the biochemical analysis was obtained from Roche Diagnostics GmbH, Mannheim, Germany.

Plant material

The plant materials were gathered from Purulia (West Bengal) in the month of July 2018. *Trapa*

*Correspondence:

Phone: +91 7838591051 (Mob.)

E-Mail: cmchandana1@gmail.com

natans L was identified and authenticated by Dr. Anjula Pandey, Principal Scientist, National Bureau of Plants Genetic Resource (NBPGR), New Delhi, and given the voucher no. NHCP/NBPGR/2013-7.

Extraction process

The plant materials were shade dried at normal room temperature (25°C) for 15 days till constant weight was attained. After that, the plant materials (500 g) were crushed using an electric grinder, and the powdered material was kept in an airtight container before the extraction. The powdered material was extracted using methanol in the Soxhlet apparatus at 70°C for 72 h. Finally, the solvent of the extract was evaporated by a rotary evaporator. The obtained extract (65.12 g) fractionation with petether, chloroform and ethyl acetate. The ethyl acetate fraction (25.5 g) was collected for the further isolation process¹¹.

A concentrated ethyl acetate fraction of *T. natans* was mixed with silica gel (200-400 mesh) and evaporated by rotary evaporator until the mixture of silica gel and extract became completely dried and in free-flowing mass condition. The ethyl acetate fraction-coated silica gel was poured into the column. *T. natans* extract coated silica settled completely on the upper surface of the silica gel of the column. The compounds slowly came out from the column along with the eluting solvent, n-hexane/EtOH (9:1, 8:2, 7:3, 6:4, 1:9 v/v). The rate of elution was 35 drops per min. At the beginning of elution, about 500 mL of the solvent (n-hexane) was allowed to pass through the column^{12,13}. Then the solvent eluting from the column was collected in the 10 mL conical flask at 15 min intervals. The TLC was carried out for each collection. The yellow crystalline compound was isolated from the fraction. The compound was characterized by UV, IR, NMR and Mass spectroscopy^{14,15}.

Acute toxicity study

The acute toxicity study was approved by the Animal Ethical Committee (Protocol No. IAEC/NIET/2019/01/08) and performed following OECD guideline 423.

For the acute toxicity study, 15 Wistar albino female rats were taken and the animals were divided into four groups, each containing three animals. Group I, the control group, received distilled water; the animals of Gr. II-IV received 5, 50 and 300 mg/kg isolated compounds, respectively. After administration of the drug, the animals were kept under observation at 30 min intervals for the first 4 h and then twice a

day for the next 14 days, after the administration of the drug. Every day, the animals were observed twice daily to find out the mortality of the rats, if any. The changes in the behaviour of the experimental animals and their other body parameters, like body wt., urination, respiration, intake of food and water, body temperature and the skin colour were observed^{16,17}.

Experiment design for hepatoprotective activity

For hepatoprotective activity, the animals were divided into four groups each containing 6 animals. The animals were subjected to the following treatments for 9 days. Before administration of paracetamol (3 g/kg p.o) to the experimental rat. Group I serve as normal control received water (2 mL/kg), Gr. II, serves as negative control, received water 2 mL/kg; Gr. III treated with silymarin (30 mg/kg); and Gr. IV had 30 mg/kg isolated flavonoids obtained from *Trapa natans* L extract. On the 10th day, paracetamol 3 g/kg.p.o was administered to all the groups except Gr. I. Food was withdrawn 12 h prior to paracetamol administration. After 24 h of paracetamol administration, the rats were sacrificed by cervical dislocation^{18,19}.

Determination of AST, ALT, ALP, and serum bilirubin

The collected blood from the experimental rats was kept in a clean, dry tube and centrifuged for 10 min at 2000 rpm. After that, the supernatant serum sample was transferred into the Eppendorf tube. Biochemical analysis was performed by a semi-automated biochemical analyzer (Microlab MC300) for determination of liver enzymes such as alkaline aminotransferase (ALT), aspartate aminotransferase (AST), alkaline phosphatase (ALP) and serum bilirubin using the common biochemical analyzer kit (Roche Diagnostics GmbH, Mannheim, Germany)^{20,21}.

Determination of liver enzyme level

The isolated livers were immediately washed with the help of saline (ice-cold) to remove the blood as much as possible. The required quantity of liver homogenates (5% w/v) was prepared using ice-cold potassium phosphate buffer (pH7.4) with the help of a homogenizer. The cell fragments and other insoluble substances were removed by centrifugation method (1000 rpm)²². The supernatant was collected and used for the testing of superoxide dismutase (SOD) adopting the method described by Vincent *et al.*²³, catalase (CAT) was determined by following the method of Gupta *et al.*²⁴ Malondialdehyde was determined according to Khan *et al.*²⁵ and hydro peroxide was tested according to Mondal *et al.*²⁶.

Histopathological study

After the collection of blood for biochemical analysis, the experimental rats were killed by cervical dislocation and the liver was dissected from the rat. The liver was washed with phosphate buffer (pH 4.7) and the histopathological studies were performed as described in Sharma *et al.*²⁷. After washing, the liver was kept in the 10% formalin solution. The liver tissues were embedded by the paraffin and sections were cut with the help of a microtome up to the 5 μm thickness. The liver tissues were stained with hematoxylin and eosin, and the slides were observed under (40X) light microscope for any histopathological changes²⁸.

Statistical analysis

All the data in this experiment are articulated as mean \pm standard error mean. Statistically, the data was analyzed by adopting one-way ANOVA, followed by Dunnett's test using the software Graph Pad Prism5. A static significance value was accepted at $P < 0.05$

Results

All the eluents having the R_f value of 0.38 were contacted together. The solvent system used for TLC analysis was ethyl acetate: acetic acid: formic acid: water (6:1:1:2). 2.5 g yellow colour compound was found from 1.5 kg powder drug. The melting point was found 302-302°C which was similar to the standard compound morin²⁹.

Identification of isolate compound

Identification of the isolated compound was done by TLC, UV, IR, NMR, and Mass spectroscopy. The maximum absorption of the isolated compound was found at 265 and 387 which were matched with the standard sample morin (Fig. 1A). The IR spectra of the isolated compound showed a strong peak at band OH stretching at 3256.45 cm^{-1} , C=O Aryl stretching of Ketone at 1662 cm^{-1} , C=C aromatic stretch 1602.06, 1519, 1452 cm^{-1} , C-O Stretching 1259.73 cm^{-1} , C-H aromatic bending at 1198, 1011 cm^{-1} (Fig. 1B). ¹H NMR spectra of the isolated compound were observed at δ 6.19, 6.42, 6.88, 7.43 for Ar-H and 12.50, 10.31, 9.62, 9.37 for Ar-OH (Fig. 2A). The ¹³C NMR spectra of the isolated compound were found at 93.81, 98.68, 103.47, 115.52, 116.06, 120.44, 161.17 for Ar-C and 176.28 for Ar-C=O. (Fig. 2B).

Acute toxicity

In the acute toxicity study, no treatment-related toxic effect or mortality was observed after oral administration of the isolated compound in a single dose of 5, 50 and

300 mg/kg. Up to 14 days' observation of all the rats, there was no notable change in their body temperature, skin, fur, eye colour, food habit, and urination; no sign of sedation or symptom of diarrhea was observed for the first 4 h in the treated and control groups. Even within the 14 days, no medication-related behavioral change, breathing-related problem, change in the skin texture, change in the habit of food consumption, body temperature or irregular change in body weights were noted.

Effect of the isolated compound on ALT, AST, ALP, total bilirubin, and total protein

The increased result of AST and ALD indicate injury or damage to the liver. From the result, it was found that in the paracetamol induced group (model control) the serum ALT, AST, ALP, total bilirubin, and total protein level were increased by 218.57 \pm 3.40 U/L, 300.4 \pm 6.12 U/L, 146.7 \pm 1.8 U/L, 0.64 \pm 0.02 mg/dL, 5.51 \pm 0.12 mg/dL, respectively which indicate the serious liver injury. Whereas in the case of the control group, the value was 42.80 \pm 2.92 U/L, 110.52 \pm 2.19 U/L, 95.15 \pm 1.84 U/L, 0.34 \pm 0.018 mg/dL and 6.92 \pm 0.12 mg/dL, respectively.

The level of serum ALT, AST, ALP and Bilirubin were reduced much lower in the case of the standard

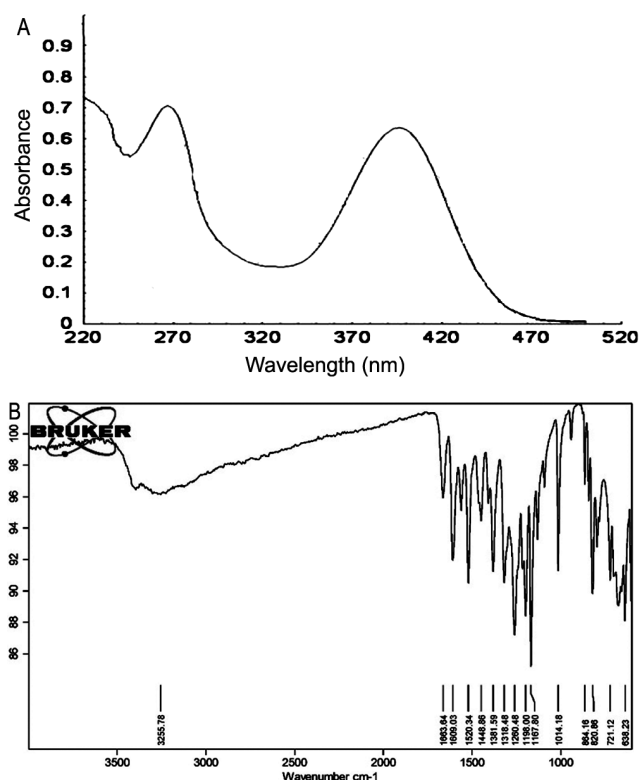


Fig. 1 — (A) UV; and (B) IR spectra of the isolated compound.

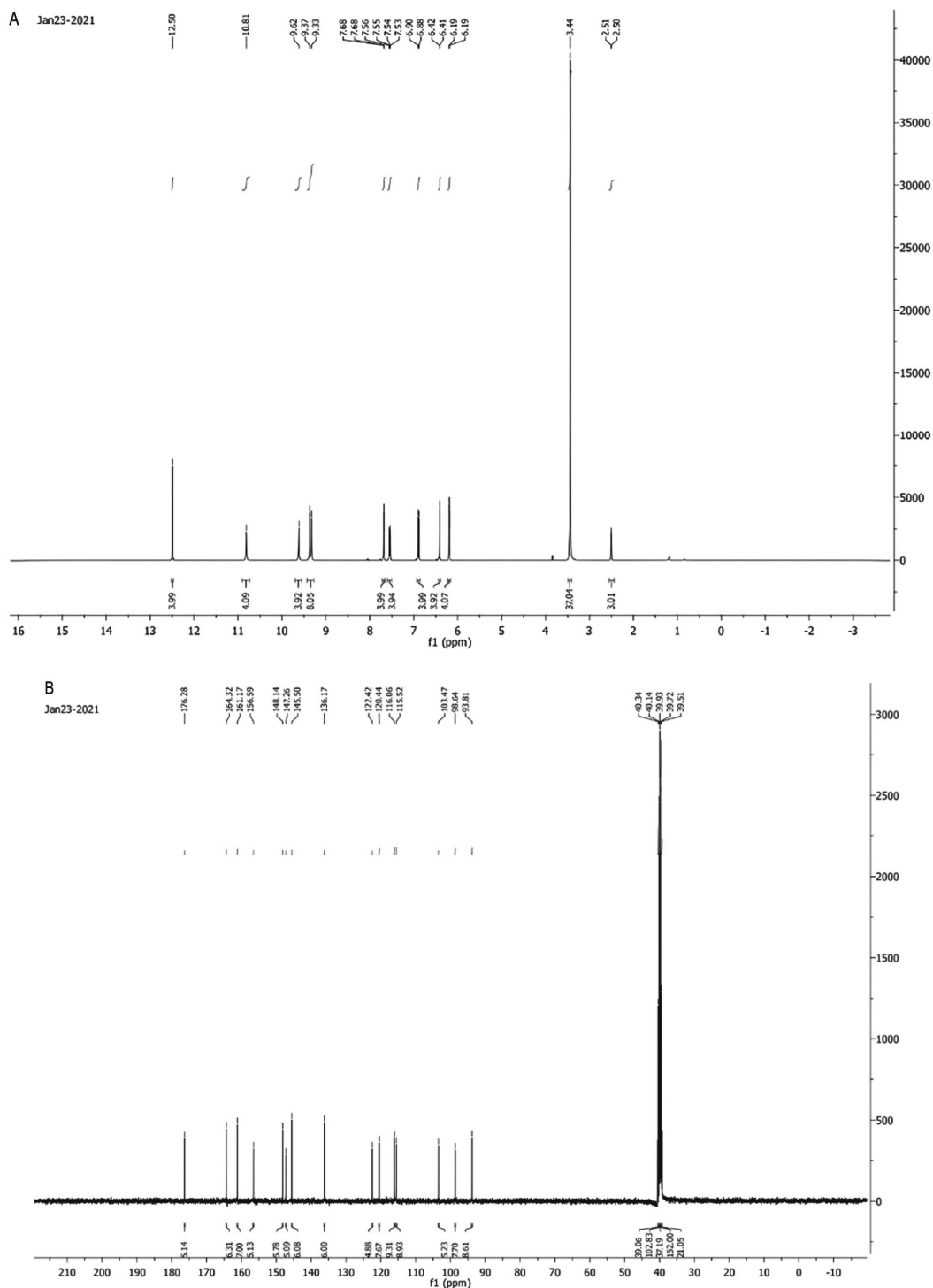


Fig. 2 — (A) ^1H NMR; and (B) ^{13}C NMR spectra of the isolated compound.

(silymarin 30 mg/kg) and isolated flavonoids (30 mg/kg body wt.), and on the other hand level of total protein was increased as given in Table 1. The standard drug and isolated compound gave approximately the same result.

Effect of lipid peroxidation and oxidation enzyme and total protein

In the case of the control group, the SOD level was decreased to 45.42 ± 1.91 mg/dL, which was very low as compared to the normal control group

Table 1 — Effect of the isolated compound on liver enzyme and biochemicals

Study Group	ALT(U/L)	AST(U/L)	ALP (U/L)	Total Bilirubin (mg/dL)	Total Protein (mg/dL)
Gr. I Normal control	42.80±2.92	110.52±2.19	95.15±1.84	0.34±0.018	6.92±0.12
Gr. II Paracetamol	218.57±3.40	300.4±6.12	146.7±1.87	0.64±0.027	5.51±0.15
Gr. III Paracetamol+silymarin (30 mg/kg)	74.20±1.42***	153.2±3.15***	87 ±1.91***	0.35±0.005***	7.15±0.32***
Gr. IV Paracetamol+isolated compound (30 mg/kg)	63.80±1.39***	160±1.53***	98.20±1.59***	0.39±0.01***	7.38±0.16***

[Value expressed by mean ± standard error mean; significance value *** $P < 0.001$ as compared to model control (only paracetamol)]

Table 2 — Antioxidant levels of various treatment groups

Treatment Group	SOD (mg/dL)	GSH (mg/dL)	CAT U/mg Protein	MDA nmol/mL	Hydroperoxides (mmol/100 g)
Gr. I Normal Control	70.83±1.13	60.33±1.49	80.50±1.23	201.5±2.1	59.2±2.5
Gr. II Paracetamol	45.42±1.91	36.83±1.20	25.45±1.76	360±4.5	90.5±5.5
Gr. III Paracetamol+Silymarin (30 mg/kg)	65.50±1.58***	52.67±2.71***	59.83±1.79***	220.5±3.2***	71.3±2.3***
Gr. IV Paracetamol+Isolated compound (30mg/kg)	63.80±1.39***	62±2.53***	58.20±1.59***	240.3±9.52***	73.8±2.16***

[Value expressed by mean ± standard error mean; significance value *** $P < 0.001$ as compared to model control (only paracetamol)]

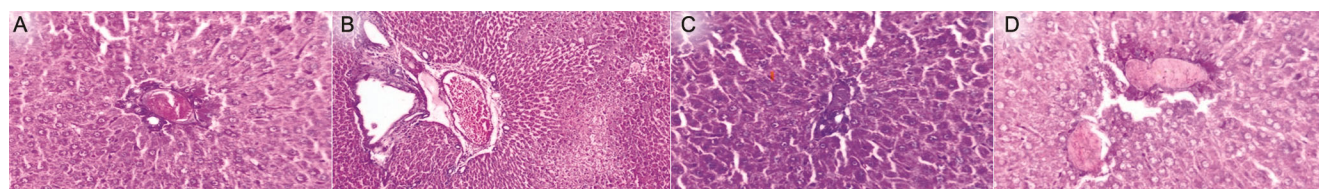


Fig. 3 — (A) Liver section of Normal control; (B) Model control (only paracetamol); (C) Standard (treated with silymarin 30 mg/kg); and (D) Test group (Treated with the isolated compound @30 mg/kg).

(70.083±1.13 91 mg/dL). The standard drug and isolated compound significantly ($P < 0.001$) increased the SOD level by 65.50±1.58, and 63.80±1.39, respectively. The same result was also observed in the case of GSH levels. The standard and test drugs were able to enhance the level of GSH 52.67±2.7 mg/dL and 62±2.53mg/dL, respectively which were very high as compared to the model control group (36.83±1.20). The level of CAT was very low in the model control group (25.45±1.76 U/mg) as compared to the normal control group (80.50±1.23). With the administration of the test drug (isolated compound) the level of CAT increased (58.20±1.59). The isolated compound showed a similar result as that of the standard drug (59.83±1.79). The serum MDA level in the model control group increased remarkably (360±4.5 nmol/mL) whereas in the case of normal control groups the level of MDA was (201.5±2.1 nmol/mL). After administration of the isolated flavonoids, the MDA level were found 240.3±9.52. The results were given in Table 2.

Histopathology of liver

The case of the normal control group (only water 1 mL/kg) revealed normal hepatocellular structure through the majority of the tissue section, with prominent nucleolus visible in the central vein. In

the case of the model control group, massive fatty change, in some area cell necrosis, increased sinusoidal spaces which were either filled with blood or edematous fluid, and loss of cellular boundaries were observed in rats' liver histogram. In the case of the standard group (silymarin 30 mg/kg) the histogram of the liver revealed normal cellular and architectural structure throughout the majority of the tissue section in some areas mild fatty change was observed. A few hepatocyte binucleations were also observed. The group treated with isolated flavonoids (30 mg/kg) liver histopathology showed normal cellular and architectural structure throughout the majority of the tissue section. However, in a few multifocal areas, mild fatty changes in hepatocytes along with increased sinusoidal space and congestion were observed (Fig. 3 A-D).

Discussion

Paracetamol is a very common drug and relatively nontoxic when administered between therapeutic doses, but in a high single dose or repeated doses cause hepatotoxicity. In the liver, the small portion of paracetamol (5-10%) is converted to N-acetyl-para-benzoquinone-imine (NAPBI) a relative metabolite by the isoform of P450 (CYP2E1, CYP2A6)³⁰. Generally, it is produced in small quantities and

immediately detoxified by the liver enzyme. But when NAPBI is present in a high amount it does not detoxify properly in the liver and causes severe liver damage³¹. Rising the level of aminotransferase compounds (ALT and AST) is the primary indication of hepatotoxicity due to the overdose of paracetamol. The level of AST and ALT is elevated when the tissue and the cells are damaged or injured. The degree of AST increments in the blood after the six-hour of cell damage³². In this experiment, administration of paracetamol increases the serum ALT, AST, ALP and bilirubin levels.

For this experiment, silymarin (30 mg) was chosen as a standard hepatoprotective drug as it is known to protect the plasma membrane of liver cells. Silymarin has the ability to reduce free radicals. Additionally, it prevents toxins from entering the liver cells. It also stimulates protein synthesis. The isolated flavonoids identified as morin reduces the elevated level of the enzyme. The effectiveness of the isolated compound 30 mg/kg is comparable to the silymarin. The hepatoprotective activity of isolated flavonoids is associated with antioxidant potentiality^{33,34}.

The elevated level of MDA indicates the enhancement of lipid peroxidation which leads to tissue damage and reduces the antioxidant defense mechanism which prevents the formation of excess numbers of free radicals^{35,36}. The morin acts as a natural protector against lipid peroxidation and reduces the elevated level of MDA. SOD and CAT are important scavengers of hydrogen peroxide and superoxide ions. These enzymes protect the cellular constituents from oxidative damage by preventing the generation of hydroxyl radicals. An isolated compound is able to increase the level of SOD and CAT and protect the liver from hydroxyl radicals^{37,38}.

Paracetamol is metabolized in the liver where the toxic byproduct of the paracetamol will be produced and the toxic product removed from the liver by forming the conjugation with glutathione³⁹. Reduced Nrf2 activity, lower GSH levels, and greater oxidative stress were linked to hepatocyte cell death in mice. Reduced Nrf2 activity, lower GSH levels, and greater oxidative stress were linked to hepatocyte cell death in mice. This finding led to the observation that liver necrosis occurs when the level of GSH levels is considerably low⁴⁰. In the case of paracetamol induce model control groups the level of GSH markedly

reduces. The test drug can able to elevate the level of GSH.

Conclusion

High doses of paracetamol cause liver damage and change the biochemical parameter in comparison to the control group. According to the experimental findings, the isolated flavonoids from *Trapa natans* plant extract treated group resists the change in the typical biochemical parameter after the administration of paracetamol. The isolated flavonoids also protect and prevent damage to liver cells. The isolated flavonoid proved effective that was comparable to the standard compound silymarin. The inhibition of reactive oxygen species by a boost in antioxidant enzymes like SOD, CAT, and GSH may be the foundation for the possible mechanism of isolated flavonoids. Based on experimental findings, it may be concluded that isolated flavonoids from plant extract have potent hepatoprotective potentiality and in the future will be used as effective drugs to treat liver problems in human beings.

Conflict of interest

Authors declare no competing interests.

References

- 1 Zhang J, Hu K, Di L, Wang P, Liu Z, Zhang J, Yue P, Song W, Zhang J, Chen T & Wang Z; Traditional herbal medicine and nanomedicine: Converging disciplines to improve therapeutic efficacy and human health. *Adv Drug Deliv Rev*, 178 (2021) 113964.
- 2 Gupta RK, Swain SR, Sahoo J, Chaudhary S & Sara US; Comparative antioxidant and hepatoprotective potential quercetin and corycavidine from *Hedyotis corymbosa* (L.) Lam. and *Solanum xanthocarpum* Schrad & Wendl. *Indian J Exp Biol*, 59 (2021) 77
- 3 Kang AM, Padilla-Jones A, Fisher ES, Akakpo JY, Jaeschke H, Rumack BH, Gerkin RD & Curry SC; The effect of 4-methylpyrazole on oxidative metabolism of acetaminophen in human volunteers. *J Med Toxicol*, 16(2020) 169.
- 4 Maeda M, Tanaka R, Aso M, Sakamoto Y, Song I, Ochiai M, Saito Y, Maekawa K, Arakawa N, Ohno Y & Kumagai Y; Hepatic adaptation to therapeutic doses of acetaminophen: an exploratory study in healthy individuals. *Clin Ther*, 42 (2020)1276.
- 5 Shakya AK; Drug-induced hepatotoxicity and hepatoprotective medicinal plants: a review. *Indian J Pharm Educ Res*, 54 (2020) 234.
- 6 Bellassoued K, Hamed H, Ghrab F, Kallel R, Van PJ, Makni AF & Elfeki A; Antioxidant and hepatoprotective effects of *Cassia angustifolia* extract against carbon tetrachloride-induced hepatotoxicity in rats. *Arch Insect Biochem Physiol*, 127 (2021)486.
- 7 Nanjaian M, Goyal M, Vasudevan R, Khan NA & Chidambaram K; Hepatoprotective effect of combined

- extracts of *Andrographis paniculata*, *Boerhavia diffusa*, *Eclipta alba* and *Picrorhiza kurroa* on carbon tetrachloride and paracetamol-induced hepatotoxicity in rats. *Indian J Tradit Knowl*, 21 (2022) 545.
- 8 Yamane Y, Mochiji M, Ichioka S, Takayanagi Y, Ishida A, Obana A & Tanito M; Effects of water chestnut (*Tarpha bispinosa* Roxb.) extract/lutein on fingertip-measured advanced glycation endproduct/carotenoid levels. *Free Radic Res*, 56 (2022) 282.
 - 9 Soliman MS, Abdella A, Khidr YA, Hassan GO, Al-Saman MA & Elsanhoty RM; Pharmacological activities and characterization of phenolic and flavonoid compounds in methanolic extract of *Euphorbia cuneata* Vahl aerial parts. *Molecules*, 26 (2021) 7345.
 - 10 Usmani S, Hussain A, Wahab S, Kushwaha P, Khatoun S, Arif M, Prakash O & Kamal M; Antioxidant potential of crude extract, flavonoid-rich fractions, and a new compound from the seeds of *Cordia dichotoma*. *Indian J Nat Prod Resour*, 12(2022) 437.
 - 11 Chaves JO, De Souza MC, Da Silva LC, Lachos-Perez D, Torres-Mayanga PC, Machado AP, Forster-Carneiro T, Vázquez-Espinosa M, González-de-Peredo AV, Barbero GF & Rostagno MA; Extraction of flavonoids from natural sources using modern techniques. *Front Chem*, 8 (2020) 507887.
 - 12 Tzanova M, Atanasov V, Yaneva Z, Ivanova D & Dinev T; Selectivity of current extraction techniques for flavonoids from plant materials. *Processes*, 8 (2020) 1222.
 - 13 Jibril FI, Hilmi AB & Manivannan L; Isolation and characterization of polyphenols in natural honey for the treatment of human diseases. *Bull Natl Res Cent*, 43 (2019) 1.
 - 14 Lin LJ, Huang XB & Lv ZC; Isolation and identification of flavonoids components from *Pteris vittata* L. *Springer Plus*, 5 (2016) 3.
 - 15 Razafindrakoto ZR, Tombozara N, Donno D, Gamba G, Nalimanana NR, Rakotondramanana DA, Andrianjara C, Beccaro GL & Ramanitrahasimbola D; Antioxidant, analgesic, anti-inflammatory, and antipyretic properties, and toxicity studies of the aerial parts of *Imperata cylindrica* (L.). Beauv. *S Afr J Bot*, 142 (2021) 222.
 - 16 Sarkar PK, Prajapati PK, Shukla VJ & Ravishankar B; Evaluation of acute, sub-acute toxicity and cardiac activity of processed borax. *J Nat Prod Indian Resour*, 8 (2017) 299.
 - 17 Aborehab NM & Boshra SA; Hepatoprotective effect of ginger and grape seed, alone and in combination orally, in paracetamol induced acute liver toxicity in rats. *Indian J Exp Biol*, 57 (2019) 281.
 - 18 Sinaga E, Fitrayadi A, Asrori A, Rahayu SE, Suprihatin S & Prasasty VD; Hepatoprotective effect of *Pandanus odoratissimus* seed extracts on paracetamol-induced rats. *Pharm Biol*, 59 (2021) 31.
 - 19 Shi Z, Li T, Liu Y, Cai T, Yao W, Jiang J, He Y & Shan L; Hepatoprotective and anti-oxidative effects of total flavonoids from Qu Zhi Qiao (fruit of *Citrus Paradisi* cv. Changshanhuoyou) on nonalcoholic steatohepatitis *in vivo* and *in vitro* through Nrf2-ARE signaling pathway. *Front. Pharmacol*, 11(2020) 483.
 - 20 Popiolek I, Hydzik P, Jagielski P, Zrodzowska M, Mystek K & Porebski G; Risk factors for hepatotoxicity due to paracetamol overdose in adults. *Medicina* 57(2021)752
 - 21 He Y, Xia Z, Yu D, Wang J, Jin L, Huang D, Ye X, Li X & Zhang B; Hepatoprotective effects and structure-activity relationship of five flavonoids against lipopolysaccharide/d-galactosamine induced acute liver failure in mice. *Int. Immunopharmacol*, 68 (2019)171.
 - 22 Dillon JF, Miller MH, Robinson EM, Hapca A, Rezaeiemami M, Weatherburn C, McIntyre PG, Bartlett B, Donnan PT, Boyd KA & Dow E; Intelligent liver function testing (iLFT): a trial of automated diagnosis and staging of liver disease in primary care. *J Hepatol*, 71 (2019) 699.
 - 23 Vincent A, Thauvin M, Quévrain E, Mathieu E, Layani S, Seksik P, Batinic-Haberle I, Vrzi S, Policar C & Delsuc N; Evaluation of the compounds commonly known as superoxide dismutase and catalase mimics in cellular models. *J Inorg Biochem*. 219 (2021) 111431.
 - 24 Gupta A, Kumar R, Ganguly R, Singh AK, Rana HK & Pandey AK; Antioxidant, anti-inflammatory, and hepatoprotective activities of *Terminalia bellirica* and its bioactive component ellagic acid against diclofenac induced oxidative stress and hepatotoxicity. *Toxicol Rep*, 8 (2021) 44.
 - 25 Khan S, Du G, Mao Y, Ahmed A, Khurshid A & Khan TU; Effects of epiphytic diatom *Licmophora paradoxa* on photosynthesis, malondialdehyde content and antioxidant enzymes activities of *Pyropia yezoensis*. *Indian J Mar Sci*, 49 (2020) 982.
 - 26 Mondal M, Hossain MM, Hasan MR, Tarun MT, Islam MA, Choudhuri MS, Islam MT & Mubarak MS; Hepatoprotective and antioxidant capacity of *Mallotus repandus* ethyl acetate stem extract against D-galactosamine-induced hepatotoxicity in rats. *ACS omega*, 5 (2020) 6523.
 - 27 Raghuvanshi S, Agrawal ND, Rawat P, Srivastava S & Shukla S; Hepatorenal protective action of *Spirulina platensis* against beryllium induced hepatorenal dysfunction and histopathological alterations in rats. *Indian J Exp Biol*, 58 (2022) 23.
 - 28 Kotadiya CR, Patel UD, Patel HB, Modi CM & Fefar DT; Evaluation of effects of *Opuntia elatior* Mill. Fruit juice and quercetin on biochemical parameters and histopathological changes in diabetic rats. *Indian J Tradit Knowl*, 17 (2018) 576.
 - 29 Trendafilova I, Mihaly J, Momekova D, Chimshirova R, Lazarova H, Momekov G & Popova M; Antioxidant activity and modified release profiles of morin and hesperidin flavonoids loaded in Mg-or Ag-modified SBA-16 carriers. *Mater Today Commun*, 24 (2020) 101198.
 - 30 Lao YE, Molden E, Kringen MK, Annexstad EJ, Sæverud HA, Jacobsen D & Hovda KE; Fatal liver failure after therapeutic doses of paracetamol in a patient with Duchenne muscular dystrophy and atypical pharmacogenetic profile of drug-metabolizing enzymes. *Basic Clin Pharmacol Toxicol*, 127 (2020) 47.
 - 31 Niu H, Sanabria-Cabrera J, Alvarez-Alvarez I, Robles-Diaz M, Stankeviciute S, Aithal GP, Bjornsson ES, Andrade RJ & Lucena MI; Prevention and management of idiosyncratic drug-induced liver injury: Systematic review and meta-analysis of randomised clinical trials. *Pharmacol. Res. Commun*, 164 (2021)105404.
 - 32 Shetty M, Shenoy S, Kumar N, Devi V, Amuthan A, Shenoy GK & Pavithra P; Kadukkai maathirai (a polyherbal traditional siddha formulation) prevents D-galactosamine

- induced hepatic necrosis in rats. *Indian J Tradit Knowl*, 19 (2020) 708.
- 33 Dwivedi PS, Patil VS, Khanal P, Bhandare VV, Gurav S, Harish DR, Patil BM & Roy S; System biology-based investigation of Silymarin to trace hepatoprotective effect. *Comput Biol Med*, 142 (2022)105223.
- 34 Mohamed Kamel GA, Harahsheh E & Hussein S; Mechanisms underlying the hepatoprotective effect of silymarin on fluoxetine-induced liver injury in rats: the implication of peroxisome proliferator-activated receptor-gamma (PPAR- γ). *Comp Clin Path*, 9 (2022) 689.
- 35 Zelber-Sagi S, Ivancovsky-Wajcman D, Fliss-Isakov N, Hahn M, Webb M, Shibolet O, Kariv R & Tirosh O; Serum malondialdehyde is associated with non-alcoholic fatty liver and related liver damage differentially in men and women. *Antioxidants*, 9 (2020) 578.
- 36 Sharifi-Rad M, Anil Kumar NV, Zucca P, Varoni EM, Dini L, Panzarini E, Rajkovic J, Tsouh Fokou PV, Azzini E, Peluso I & Prakash MA; Lifestyle, oxidative stress, and antioxidants: Back and forth in the pathophysiology of chronic diseases. *Front. Physiol*, 11 (2020) 694.
- 37 Gogoi N, Gogoi A, Neog B, Baruah D & Singh KD; Antioxidant and hepatoprotective activity of fruit rind extract of *Garcinia morella* (Gaertn.) Dear. *Indian J Nat Prod Resour*, 8 (2017)132.
- 38 Chen L, Li K, Liu Q, Quiles JL, Filosa R, Kamal MA, Wang F, Kai G, Zou X, Teng H & Xiao J; Protective effects of raspberry on the oxidative damage in HepG2 cells through Keap1/Nrf2-dependent signaling pathway. *Food Chem Toxicol*, 133 (2019) 110781.
- 39 Li J, Chiew AL, Isbister GK & Duffull SB; Sulfate conjugation may be the key to hepatotoxicity in paracetamol overdose. *Br J Clin Pharmacol*, 87 (2021) 2392.
- 40 Frampton G, Reddy P, Jefferson B, Ali M, Khan D & McMillin M; Inhibition of thrombospondin-1 reduces glutathione activity and worsens acute liver injury during acetaminophen hepatotoxicity in mice. *Toxicol Appl Pharmacol*, 409(2020)115323.