



NOTES

Waste leachate induces histological alterations in *Limicolaria aurora* (Jay, 1839) digestive gland

Ugokwe CU^{1*}, Okafor FC¹, Ezewudo BI¹, Olagunju TE³ & Njoku EU²

¹Department of Zoology and Environmental Biology;

²Department of Plant Science and Biotechnology, University of Nigeria, Nsukka, Enugu, Nigeria

³Department of Biology/Microbiology/Biotechnology, Alex Ekwueme Federal University, Ndufu-Alike Ikwo, Nigeria

Received 12 May 2020; revised 24 April 2022

Unsanitary open dumping and burning of wastes in dumpsites results to constant leaching of waste pollutants into the surrounding environment with attendant harmful consequences on wildlife and public health. Here, we investigated the histological effects of Onitsha municipal waste leachate on the Giant African land snail, *Limicolaria aurora* (Jay 1839). The histopathological effects of waste leachate on the digestive cells of the snails were examined following standard protocols. Snails were exposed to different concentrations (0, 6.25, 12.5, 25.0 and 50.0%) of the leachate for a total duration of 21 days. Histological results obtained showed that waste leachate caused dose and duration dependent alterations in the digestive glands of *L. aurora*. Obvious histological variations were observed in snails exposed to 50% concentrations of the leachate compared to other doses. Observed histological changes were mainly degeneration of the digestive tubules, fragmentation and disappearance of the digestive cells, marked increase in excretory cells, necrosis and epithelia sloughing. This study therefore highlights the potential toxicity of waste leachate of causing mild to severe damage in the tissues of organisms. Reinforcing the fact, that waste leachate contains a mix of toxic substances that could pose a severe injury to the biological system of surrounding biota, including humans.

Keywords: Environmental pollution, Giant African land snail, Waste management

Urbanization comes with increase in waste generation with serious implication when the rapid growing waste rates are not efficiently managed. Poor and unscientific management of these generated wastes has resulted in serious environmental hazard¹. The volume of solid waste generated in Nigeria continues to increase at an alarming rate than the capacity of the responsible waste agencies to improve on the waste management, as some major roads and markets

experience accumulated waste from commercial and industrial activities¹. At current population growth rate of over 210 million² and economic growth, waste generation is projected to increase over the next few years. Open dumping and burning of waste remain the usual unhygienic method of waste management in Nigeria³. Generation of toxic leachates has been a major problem arising from this uncontrolled waste dumping with serious public health concern⁴.

Leachates constitute a wide range of xenobiotic organic compounds, macro-inorganic compounds, heavy metals and microorganisms, which cause severe human health problems⁵. Small amounts of leachates can pollute large volume of ground and surface water ecosystem⁶. Studies have shown that pollutants present in leachates have damaging effects on living cells^{3,5}. Waste leachate has been associated with increases in cancer incidence, diseases outbreaks, reproduction and developmental problems among human populations residing close to landfill sites⁷. Owing to the grave consequences of waste leachate exposure resulting from inappropriate waste management, studies have focused on biomonitoring the contaminants in leachates from dumpsites⁸⁻¹⁰.

Land snails are the most species-rich group of terrestrial mollusks with enormous ecological importance¹¹. Giant African land snails (*Limicolaria aurora* Jay) are regular delicacy in diets of some rural communities in Nigeria. They form cheap source of protein to the local populace and plays important ecological roles. These snails have been recognized as a suitable bioindicator of environmental stress due to their ecological distribution, easy sampling, tolerance to stress and ability to bio accumulate compounds¹². In snails, the digestive gland plays an important role in accumulation, biotransformation and detoxification of various substances, making it the target organ in environmental pollution evaluation¹³. Therefore, histological alterations in the digestive gland of snail is a significant bioindicator of environmental pollution¹³.

Thus, in this study, we did histological analysis of the digestive gland of giant African land snail *Limicolaria aurora* to understand the potential tissue damaging effect of waste leachate from Onitsha municipal waste dumpsite.

*Correspondence:
E-Mail: ugokwecollins@gmail.com

Materials and Methods

Description of study area

Onitsha, one of the major cities in Anambra State of eastern Nigeria is one of the most important commercial centers in sub-Saharan Africa with significant human population. More than 90% of solid waste generated in Onitsha metropolis is deposited in open dumpsite without any initial source separation. Onitsha municipal waste dumpsite is located along Onitsha-Owerri road Obosi, Ogbaru Local Government (latitude 06° 6' N and longitude 06° 48' E) Anambra State, Nigeria. This is the main dumping sites receiving most of the solid waste from Onitsha metropolis for over 10 years, with an average of 125,000 tonnage of wastes per month³. The dumpsite is not equipped with a leachate collection and treatment system; thus, leachate produced is freely discharged and possibly pollute the surrounding aquatic and terrestrial environment.

Leachate collection

Raw leachates were collected from 15 leachate wells (holes in the ground), at different point on the dumpsite and thoroughly mixed to provide a homogenous and composite representative sample. The leachate was transported to the laboratory and examined for some physicochemical parameters as described in our previous study²

Experimental procedure

Live samples of adult *Limicolaria aurora* (average weight of 10.47±0.42 g) were commercially obtained from a snail farm in Nsukka, Enugu State. The specimens collected were identified according to Crowley & Pain¹⁴ and were transported to the animal house of Department of Zoology and Environmental Biology, University of Nigeria, Nsukka. Snails were acclimatized for six days according to the methods of Thompson & Cheney¹⁵ and Ebenso *et al.*¹⁶. Snails were reared in plastic boxes 12×12×60 cm³ with lids perforated for ventilation, under constant conditions with a temperature cycle of 27±2°C. They were fed *ad libitum* with freshly chopped green pawpaw (*Carica papaya*) leaves during the period of acclimatization. The use of these snails was in accordance with the Ethics and Biosafety Committee of Faculty of Biological Sciences, University of Nigeria Nsukka (Reference number – UNN/FBS/EC/1015). The experiment was carried out under the natural photoperiod prevalent at Nsukka (Nigeria) in the month of August.

Five concentrations (0, 6.25, 12.5, 25.0 and 50.0%) of the leachate sample (v/v; leachate: dechlorinated tap water) were prepared. Sterilized Loamy soil was moistened with the different treatment solutions, placed in their respective boxes up to 2 cm deep. This serves as substrate and source of exposure. Ten (10) snails each were randomly allotted to each plastic boxes of each concentration and the control. Oral application of leachate samples was also given to the snails; pawpaw (*C. papaya*) leaves were presented to snails at different concentrations. These pawpaw leaves were contaminated by completely dipping them in their respective treatment concentrations, and dried at 27°C for 5 min before feeding it to the snails. Snails were fed and watered at 1700 h each day. During the 21-day exposure, three snails from each group was randomly selected at interval (day 7, 14 and 21) for the histopathology analyses.

Histopathological analysis

Slices of the digestive gland from exposed and control snails were processed as described by Lance *et al.*¹⁷. Tissues were fixed in 10% phosphate buffered formalin for 48 h and were subsequently trimmed, dehydrated in 4 grades of alcohol (70%, 80%, 90% and absolute alcohol), cleared in xylene and embedded in molten wax. On solidifying, the blocks were sectioned, 5 µm thick with a rotary microtome, floated in water bath and incubated at 60°C for 30 min. The 5 µm thick sectioned tissues were subsequently cleared in 3 of xylene and rehydrated in 3 grades of alcohol (90, 80 and 70%). The sections were then stained with Hematoxylin for 15 min. Blueing was done with ammonium chloride. Differentiation was done with 1% acid alcohol before counterstaining with Eosin. Permanent mounts were made on degreased glass slides using a mountant; DPX. The prepared slides were examined with a Motic™ compound light microscope using 4X, 10X and 40X objective lenses. The photomicrographs were taken using a Motic™ 5.0 megapixels microscope camera at 160X and 400X magnification.

Statistical analysis

Biological assessment was done to identify histopathological alterations in the digestive glands of the snails. Pathological changes observed in the digestive glands were classified in four degrees of occurrence: absent (0), rare (1), few (2), common (3) and very common (4) from each of the three snails per exposure.

Result and Discussion

Physicochemical characteristics of leachate

Table 1 shows the physicochemical parameters and heavy metals analyzed in the waste leachate sample. The values of COD, BOD, TDS, hardness, alkalinity, chlorides, phosphate, sulphate, sodium, nitrate, ammonia, and the heavy metal analysed were high compared to standard permissible limits.

Histological Observation of the Digestive gland

The histological changes of digestive gland exposed to different concentrations of the waste leachate for 21 days are shown in Figs 1-3 and Table 2.

Table 1 — Physical and chemical characteristics of Onitsha Municipal Waste leachate

Parameters ⁺	OWL	USEPA	NESREA
pH	8.20±0.1	6.5-8.5	6.0-9.0
Chemical Oxygen Demand (COD)	464±74.9	410	90
Biochemical Oxygen Demand (BOD)	263±52.8	-	50
Total Dissolved Solids (TDS)	1328.73±69.3	500	500
Hardness	259±173.9	0-75	-
Alkalinity	387±116.4	20	150
Conductivity	383±50.6	-	125
Chloride	951±164.9	250	250
Ammonia	16.82±5.2	0.02	1.0
Phosphate	288.39±10.9	-	2.0
Nitrate	14.03±1.5	10	10
Sulphate	379.02±16.4	250	250
Sodium	47.92±1.2	-	0.50
Potassium	55.18±0.6	-	100
Calcium	38.04±3.2	-	50
Lead	0.73±0.2	0.015	0.05
Cadmium	0.47±0.2	0.05	0.2
Copper	1.93±0.5	1.0	0.5
Iron	2.05±0.2	0.3	-
Zinc	14.74±4.5	-	6.0-9.0

[NESREA, National Environmental Standards and Regulations Enforcement Agency¹⁸; USEPA, United State Environmental Protection Agency (2006). (www.epa.gov/safewater/mcl.html). Source: Ugokwe *et al.*³]

Table 2 — Frequency and severity of histopathological alterations in digestive gland of snails exposed to Onitsha municipal waste leachate

Duration Conc. (%)	Day 7					Day 14					Day 21				
	0	6.25	12.50	25.00	50.00	0	6.25	12.50	25.00	50.00	0	6.25	12.50	25.00	50.00
Histological changes															
Increase Excretory cell	0	2	3	3	3	1	4	3	3	4	1	4	4	4	4
Necrosis	0	0	1	2	2	0	0	2	2	1	0	1	2	2	3
Hypertrophic tubules	0	1	1	1	1	0	1	3	2	2	0	2	3	3	3
Congestion	0	1	0	1	0	0	1	1	1	3	0	3	4	3	4
Expanded lumen	0	0	0	1	1	0	0	0	2	4	0	2	2	3	4
Vacuolation	0	0	0	1	2	0	1	1	3	3	0	4	4	4	4
Degeneration	0	0	1	1	1	0	0	1	2	3	0	3	3	4	4

[Severity of snail digestive gland histological changes were assessed using the following scale: 0 = a change that was either absent or sporadic in all animals of a group; 1 = a change that was rare in all animals of a group; 2 = a change that was found in a few animals of a group; 3 = a change that was relatively common in all animals of a group; and 4 = a change that was very often found in all animals of a group]

Observation in control groups

The digestive gland sections of snails of the control group showed normal microscopic anatomy of the digestive glands (Fig. 1A). The gland showed numerous variably sized tubules surrounded by thin circular fibro-muscular layer. Each tubule is lined by a single layer of columnar to irregular shaped cells consisting of predominantly digestive cells (dc); with less excretory cells (ec) and calcium cells (cc) (Fig. 1B).

Digestive cells constitute the major cellular component of the digestive gland tubule epithelium. They are columnar with flattened or slightly rounded apical surfaces bearing well-developed brush border. The basally located nuclei of digestive cells are rounded or oval in outline with condensed chromatin and a single nucleolus. Calcium cells are fewer than digestive cells and they occur either singly or in pairs in the tubules. They have pyramidal shape with narrow distal end and a marked broad base. The excretory cells are ovoid, containing a large cytoplasmic vacuole with golden brown excretory granules. The excretory products are accumulated in the vacuole often in the form of a large brown body. The nucleus is small and pressed flat against the cell base.

Treatment groups at Day 7

The treatment groups at day 7 showed a deviation from its normal microscopic architecture compared to the control. In the group exposed to 6.25 and 12.5% of the leachate, the tubules were mostly hypertrophic and showed increase in the population of excretory cells and calcium cells in relation to the digestive cells (Fig. 2A). In the groups exposed to higher concentrations, the tubules appear hypertrophied and show necrosis with accentuation of the interlobular connective tissues (Fig. 2B). Sloughing of the epithelia tubules with expanded lumen was also observed (Fig. 2C)

Treatment groups at Day 14 and 21

The treatment groups at days 14 and 21 showed a severe deviation from its normal microscopic

architecture compared to the control. Marked increase in the population of excretory cells (ec) were observed in these groups (Fig. 3). Necrosis of tubules (N) with accentuation of the interlobular connective tissues (I) were mainly observed at 6.25% concentration (Fig. 3B). At higher concentrations of 12.5 and 25.0%, severe widespread necrosis and sloughing of the tubular epithelia (Fig. 3 A & B) were observed. The sloughed cells appear in clusters within the expanded lumen of the tubules while distribution of the constituent cells of the tubules was not affected. The entire epithelial cells show

marked vacuolar degenerative changes (Fig. 3C) at the highest concentration (50%). The affected cells appear swollen, containing multiple tiny or single large clear cytoplasmic vacuoles (Fig. 3D).

Waste leachate is a major source of pollution in aquatic and terrestrial environment with antecedent threats to biota. These leachates contains a hazardous cocktail of organic and inorganic compounds that interplays and possibly induce cascades of biological damages¹⁹. This study investigated the histological effects of municipal waste leachate on the digestive gland of land snails. Histological changes in digestive gland are useful biomarkers of hazardous exposure²⁰. The digestive gland is responsible for digestive enzyme production, nutrient absorption, endocytosis of certain food ingredients, food storage and excretion²¹. It is comparable to the liver in humans and most target organ in toxicological findings due to its role in excretion of xenobiotics, biotransformation and detoxification. Therefore, it is most susceptible organ in mollusk to hazardous waste chemicals.

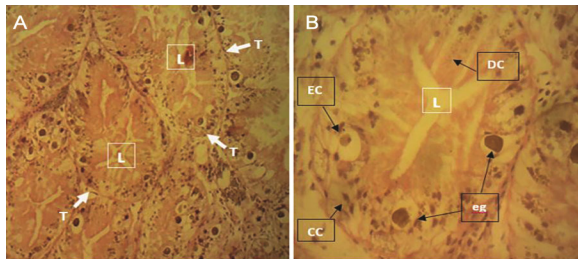


Fig. 1 — (A) Digestive gland; and (B) Digestive tubules of snails exposed to 0.0% concentration of the leachate. [T = tubules; DC = digestive cells; EC = excretory cells; CC = calcium cells; L = lumen; eg = excretory granule. H & E 160X; 400X]

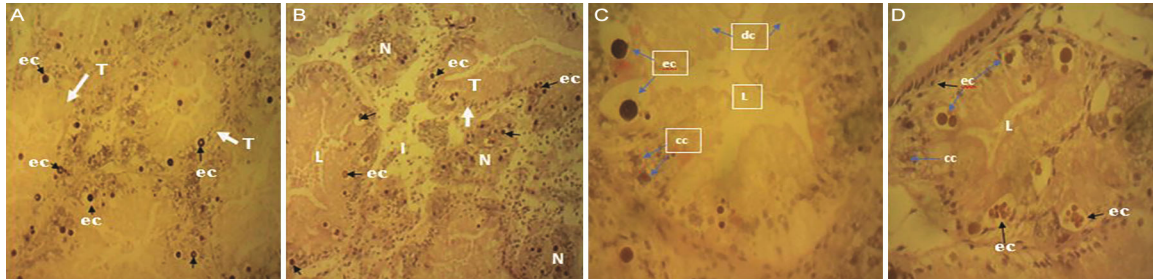


Fig. 2 — Histological sections of digestive gland of exposed snails showing (A) remarkable increase in the number of excretory cells and partial degeneration of some digestive cells; (B) Necrosis of tubules with accentuation of the interlobular connective tissues and increased excretory granules; (C) Degeneration of digestive cells with expanded Lumen; and (D) Sloughed tubule with increased excretory granules. [T = tubules; N = necrosis; I = interlobular connective tissues; dc = digestive cells; ec = excretory cells; cc = calcium cells; L = lumen. H&E 160X; 400X]

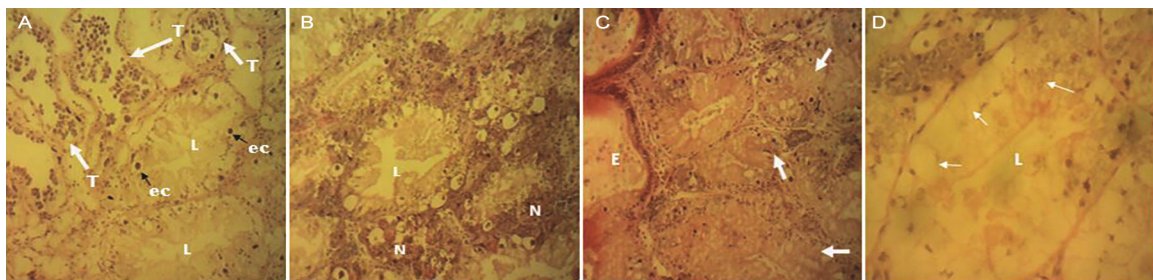


Fig. 3 — Histological sections of digestive gland of exposed snails showing; (A) widespread necrosis and sloughing of the tubular epithelia (T). The sloughed cells appear in clusters within the lumen of the tubules and excretory granules (ec); (B) Necrosis and sloughing of the epithelia in tubules (N), the entire epithelial cells show varying degrees of vacuolar degenerative changes; (C) Marked hypertrophy of the tubules with vacuolar degeneration of the epithelia (arrow), Esophagus (E); and (D) Entire epithelial cells show marked vacuolar degenerative changes. The affected cells appear swollen, containing multiple tiny or single large clear cytoplasmic vacuoles (arrow). [H&E 160X; 400X].

The results observed indicated that the alterations in digestive glands were dose and duration dependent. The investigation at day 7 and 14 showed degeneration of the digestive tubules, disappearance of the digestive cells and changes in the basement membrane in a dose-duration-dependent manner, resulting to a marked deterioration of the tissues at the highest concentrations. These results are in accordance with the findings of Radwan *et al.*²² whom stated that the structural changes and the loss of digestive cells in snails are general responses after an exposure to pollutants. Valavanidis *et al.*²³ also detailed that the deterioration of the digestive cells induced changes in the digestive process which can be attributed to the ingestion of chemical pollutants.

At day 21, this study recorded marked tissue changes in the digestive gland of *L. aurora* as shown by the visible structural changes in snails exposed at different doses. These marked changes were obvious in snails exposed to waste leachate at 25.0 and 50.0% concentrations. The histopathological responses observed when exposed to lower concentrations were mainly changes in epithelial hyperplasia, hypertrophied tubules, disappearance of digestive cells and marked increase of excretory cells. At higher concentrations, accentuation of the interlobular connective tissues, necrosis and sloughing of the epithelia with varying degrees of vacuolar degenerative changes were observed. Further histological examination at high concentrations revealed clustered sloughed cells, hemolymphatic spaces between the tubules with a more expanded lumen and desquamation of epithelial cells, accompanied by hypertrophy and swelling. This result suggested that the waste leachate contain mixture of hazardous compounds that synergistically capable of causing severe tissue damages in *L. aurora*. This finding is congruent with that of Radwan *et al.*²². Observed damage in the cells could lead to the disruption in intercellular exchange and fluidity, which might often result to cellular necrosis²². Similar findings are reported in the adults of *Helix aspersa* fed with copper-contaminated diet which exhibited significant effects of copper dose on the hepatopancreatic epithelium cells and digestive glandular epithelium area²⁰. Gust *et al.*²⁴ also reported histological lesions in the digestive gland of New Zealand mudsnail (*Potamopyrgus antipodarum*), which hypertrophy of cells and vacuolization of digestive cells were observed.

The digestive cells of *L. aurora* exposed to different concentrations of leachates showed different degrees of morphological alterations, which could be

attributed to the differences in their different phases of activity. This is in accordance with the earlier report by Moore and Halton²⁵ who reported phases of absorption, digestion and fragmentation in the cycle of the digestive cells of *L. truncatula*. Dimitriadis and Konstantinidou²⁶ also reported that the cell changes observed in the digestive gland epithelium of *H. lucorum* were regarded as different phases of digestive cell activity. Contrast to the control, there were decrease digestive cells and irregular cell structures of *L. aurora* treated with varying concentrations of waste leachate. This might be due to the fact that digestion and absorption of nutrients mainly occur in the digestive cells, and absorption of pollutants might alter their structure and abundance. Additionally, it was also observed that waste leachate exposure might result in extensive digestive-cell breakdown and release of cytoplasmic content into the digestive gland lumen of *L. aurora*. This collaborated with the findings of Bowen and Davies²⁷ and Oxford and Fish²⁸ in *Arion hortensis* and *Cepaea nemoralis*, where release of enzymes from the cytoplasm of digestive cells was associated to high rate of cell autolysis. Comparable findings were reported in the digestive cells of *Littorina littorea* exposed to organic pollutants²⁹ and in digestive cells of *Mytilus galloprovincialis* after exposure to heavy metals³⁰.

Increased calcium and excretory cells in the digestive glands were observed, suggesting that these cells are specialized for accumulation and elimination of toxic compounds^{31,32}. These results agreed with the findings of Hamed *et al.*³³ who found that methomyl-treatment increased the number and size of excretory granules after 5 and 7 days exposure to *E. vermiculata*. Similarly, Aioub *et al.*³⁴ observed an increase in the number of excretory cells in the digestive gland of *E. vermiculata* after exposure to oxamyl. Additionally, Chabicovsky *et al.*³⁵ showed that heavy metal pollutants, such as Cd, Cu and Zn, induce increased number of calcium and excretory cells at the cost of digestive cell numbers. They suggested that dying cells are phagocytosed by calcium cells. In addition, calcium shows multiple roles in gastropods and other mollusks in which they are regarded as a component concerned in detoxification of heavy metals^{31,36}.

Conclusion

In this study, we observed histopathological alterations in the digestive gland of *Limicola aurora* induced by the waste leachate in a concentration and duration dependent manner. It highlights the potential

toxicity of waste leachate of causing mild to severe damage in the tissues of organisms. These observed tissue damage might be the endpoint of cascade of physiological alterations caused by the waste leachate in an organism. The findings suggest that the waste leachate may contain a mix of toxic substances that could pose a severe injury to the biological system of surrounding biota, including humans. This study further advocated the use of histopathological investigation and the sensitivity of the giant African land snail in biomonitoring the toxicity of environmental pollutants that may pose public health concern.

Acknowledgment

Authors acknowledge the tissue processing support of Dr. Chukwunonso Ezeasor, Department of Veterinary Pathology and Microbiology, Faculty of Veterinary Medicine, University of Nigeria, Nsukka.

Conflict of Interest

Authors declare no competing interests

References

- Ogunlaja, A, Abarikwu SO, Otuechere CA & Oshoro OO, Characterization of leachates from waste landfill sites in a religious camp along Lagos-Ibadan expressway, Nigeria and its hepatotoxicity in rats. *Chemosphere*, 217 (2019) 636–645.
- National Bureau of Statistics. Central Data Catalog - National Bureau of Statistics (2021) <https://www.nigerianstat.gov.ng>. Accessed March 26, 2022.
- Ugokwe CU, Okafor FC, Okeke PC, Ezewudo BI & Olagunju TE, Induction of Genetic Alterations and Oxidative Stress in Giant African Land Snail (*Limicolaria aurora*) Exposed to Municipal Waste Leachate. *Rev Toxicol*, 37 (2020) 19.
- Ibor OR, Eni G, Andem AB, Bassey IU, Arong GA, Asor J, Regoli F & Arukwe A, Biotransformation and oxidative stress responses in relation to tissue contaminant burden in *Clarias gariepinus* exposed to simulated leachate from a solid waste dumpsite in Calabar, Nigeria. *Chemosphere*, 253 (2020) 126630
- Rautela R, Arya S, Vishwakarma S, Lee J, Kim KH & Kumar S, E-waste management and its effects on the environment and human health. *Sci Total Environ*, 773 (2021) 145623.
- Ankit K, Lala S, Virendra K, Jaya T, Sweta A, Shalu R, Jiwan S & Kuldeep B, Electronic waste and their leachates impact on human health and environment: Global ecological threat and management. *Environ Technol Innov*, 24 (2021) 102049
- Alimba CG, *DNA and systemic damage induced by landfill leachates and health impacts of human exposure to landfills in Lagos and Ibadan, Nigeria*, (Ph.D thesis, Department of Zoology, University of Ibadan, Nigeria), 2013.
- Purchase D, Abbasi G, Bisschop L, Chatterjee D, Ekberg C, Ermolin M, Wong MH, Global occurrence, chemical properties, and ecological impacts of E-wastes (IUPAC Technical Report). *Pure Appl Chem*, 92 (2020) 1733.
- Stamps BW, Lyles CN, Suflita JM, Masoner JR, Cozzarelli IM, Kolpin DW & Stevenson BS, Municipal solid waste landfills harbor distinct microbiomes. *Front Microbiol*, 7 (2016) 1e11.
- Njoku PO, Edokpayi JN & Odiyo JO, Health and Environmental Risks of Residents Living Close to a Landfill: A Case Study of Thohoyandou Landfill, Limpopo Province, South Africa. *Int J Environ Res Public Health*, 16 (2019) 21.
- Sibiya I, Poma G, Cuykx M, Covaci A, Adegbenro PD & Okonkwo J, Targeted and non-target screening of persistent organic pollutants and organophosphorus flame retardants in leachate and sediment from landfill sites in Gauteng Province, South Africa. *Sci Total Environ*, 653 (2019) 1231e1239.
- Khanam S, Kazmib QB & Iqbal F, Local dispersal of land snail *Zootecus insularis* (Ehrenberg, 1831) (Gastropoda: Subulinidae) shells in mangroves of Karachi. *Indian J Geo-Mar Sci*, 49 (2020) 1869
- Sharaf HM, Salama MA & Abd El-Att MS, Biochemical and Histological Alterations in the Digestive Gland of the Land Snail *Helicella vestalis* (Locard, 1882) Exposed to Methiocarb and Chlorpyrifos in the Laboratory. *J Cytol Histol*, 6 (2015) 327. doi:10.4172/2157-7099.1000327
- Crowley TE & Pain T, A monographic revision of the African Land Snails of the Genus *Limicolaria*. *Sci. Zool.* 177 (1970) 1
- Thompson R & Cheney S, Raising Snails. *Special reference briefs* (96-05) (USDA, Maryland), 1996, 42.
- Ebenso IE, Chukwu S, Udo S, Ukpai CU, Udo MT, Umanah U, Isang A & Akam A. Some behavioural responses of *Limicolaria aurora* exposed to gramoxone. *Nigerian J Physiol Sci*, 19 (2004) 82
- Lance E, Paty C, Bormans M, Brient L & Gerard C, Interactions between cyanobacteria and Gastropods. II. Impact of toxic Planktothrix agardhii on the life-history traits of *Lymnaea stagnalis*. *Aquat Toxicol*, 81 (2007) 389.
- NESREA (Federal Republic of Nigeria Official Gazette), *National Environmental (sanitation and waste control)*. Vol. 60, (Federal Government of Nigeria printer, Abuja FGP 112/102009/L000 (OL54), 2009, 1057.
- Ogunlaj A, Abarikwu SO, Otuechere CA & Oshoro OO, Characterization of leachates from waste landfill sites in a religious camp along Lagos-Ibadan expressway, Nigeria and its hepatotoxicity in rats. *Chemosphere*, 217 (2019) 636e645.
- Snyman RG, Reinecke SA & Reinecke AJ, Quantitative changes in digestive gland cells and oocytes of *Helix aspersa*, as biomarkers of copper oxychloride exposure under field conditions. *Bull Environ Contam Toxicol*, 83 (2009) 19.
- Owen G, Digestion. In: *Physiology of Mollusca*. (Ed. Wilbur KM & Yonge CM; Academic Press, New York), 2012, 53.
- Radwan MA, Essawy AE, Abdelmeguid NE, Hamed SS & Ahmed AE, Biochemical and histochemical on the digestive gland of *Eobania vermiculata* snails treated with carbamate pesticides. *Pest Biochem Physiol*, 90 (2008) 154.
- Valavanidis A, Vlahogianni T, Dassenakis M & Scoullos M, Molecular biomarkers of oxidative stress in aquatic organisms in relation to toxic environmental pollutants. *Ecotoxicol Environ Saf*, 64 (2006) 178.

- 24 Gust M, Buronfosse T, Geffard O, Coquery M, Mons R, Abbaci K, Giamberini L & Garric J, Comprehensive biological effects of a complex field poly-metallic pollution gradient on the New Zealand mudsnail *Potamopyrgus antipodarum* (Gray). *Aquat Toxicol*, 101 (2011) 100.
- 25 Moore MN & Halton DW, Histochemical changes in the digestive gland of *Lymnaea truncatula* infected with *Fasciola hepatica*. *Z. Parasitenk*, 43 (1973) 1.
- 26 Dimitriadis VK & Konstantinidou V, Origin of the excretory cells in the digestive gland of the land snail, *Helix lucorum*. *Malacologia*, 44 (2002) 145.
- 27 Bowen ID & Davies P, The fine structure and distribution of acid phosphatase in the digestive gland of *Arion hortensis* (F.). *Protoplasma*, 73 (1971) 78.
- 28 Oxford GS & Fish LJ, Ultrastructural localization of esterase and acid phosphatase in digestive gland cells of fed and starved *Cepaea nemoralis* (L.). *Protoplasma*, 101 (1979) 186.
- 29 Cajaraville MP, Robledo Y, Etxeberria M & Marigomez I, Cellular Biomarkers as Useful Tools in the Biological Monitoring of Environmental Pollution: Molluscan Digestive Lysosomes. In: *Cell Biology in Environmental Toxicology*, (Ed. Cajaraville MP, University of the Basque Country Press Service, Bilbao, Ukraine), 1995, 29.
- 30 Domouhsidou GP & Dimitriadis VK, Ultrastructural localization of heavy metals (Hg, Ag, Pb and Cu) in gills and digestive gland of mussels *Mytillus galloprovincialis* (L.). *Arch Environ Contam Toxicol*, 38 (2000) 472.
- 31 Snyman R, Reinecke A & Reinecke S, Quantitative changes in the digestive gland cells of the snail *Helix aspersa* after exposure to the fungicide copper oxychloride. *Ecotoxicol Environ Saf*, 60 (2005) 47.
- 32 Andrews EB, The fine structure of the excretory and venous systems of the neogastropods *Nucella lapillus* and *Buccinum undatum* and its functional and phylogenetic implications. *J Mollus Stud*, 76 (2010) 211
- 33 Hamed SS, Abdelmeguied NE, Essawy AE, Radwan MA & Hegazy AE, Histological and Ultrastructural Changes Induced by Two Carbamate Molluscides on the digestive Gland of *Eobania vermiculata*. *J Biol Sci*, 7 (2007) 1017.
- 34 Aioub AA, Ismail SA & Mohamdein AA, Toxicological and histological studies on some pesticides-treated land snails. *Proc ICBS*, 1 (2000) 19
- 35 Chabicovsky M, Klepal W & Dallinger R, Mechanisms of cadmium toxicity in terrestrial pulmonates: Programmed cell death and metallothionein overload. *Environ Toxicol Chem*, 23 (2004) 648.
- 36 Adams SM, Shorey CD & Byrne M, An ultrastructural and microanalytical study of metal-ion content in granular concretions of the freshwater mussel *Hyridella depressa*. *Micron*, 28 (1997) 1.